

Post-ischemic Administration of Vascular Endothelial Growth Factor Inhibitor in a Rat Model of Cerebral Venous Infarction

Hitoshi MIYAKE,¹ Ichiro NAKAGAWA,¹ Yasuhiro TAKESHIMA,¹
Fumihiko NISHIMURA,¹ Young-Su PARK,¹
Mitsutoshi NAKAMURA,¹ and Hiroyuki NAKASE¹

¹Department of Neurosurgery, Nara Medical University, Kashihara, Nara

Abstract

Cerebral venous ischemia can result in severe brain edema. Inhibition of vascular endothelial growth factor (VEGF) activity by a neutralizing antibody can completely block the hypoxia-induced increase in vascular permeability. VEGF, which induces angiogenesis, also acts as a vascular permeability (VP) factor. We previously showed that inhibition of VEGF attenuates VP and reduces cerebral venous infarction (CVI) in the acute stage. The present study investigated the therapeutic time window during which inhibition of VEGF can reduce CVI in a rat two-vein occlusion (2-VO) model. A 2-VO model was created by photochemically occluding two adjacent cortical veins. Male Wistar rats (n = 42) were assigned to one of four groups: Group 1 was treated with a VEGF antagonist at 24 hours after 2-VO (n = 11); Group 2 was treated with phosphate-buffered solution (PBS) at 24 hours after 2-VO (n = 11); Group 3 was treated with a VEGF antagonist at 48 hours after 2-VO (n = 10); and Group 4 was treated with PBS at 48 hours after 2-VO (n = 10). The developing ischemic infarct was evaluated histologically at 7 days after 2-VO. CVI areas were significantly smaller in Group 1 than in Groups 2, 3, and 4 ($p < 0.05$) but were similar when comparing Groups 3 and 4. Anti-VEGF therapy was effective in reducing CVI in rats if started within 24 hours after 2-VO.

Key words: cerebral venous infarction, vascular endothelial growth factor, antagonist, brain edema

Introduction

Brain edema is associated with almost all intracranial lesions, including major cerebral infarcts, hemorrhages, trauma, infections, and tumors. However, the pathophysiology of cell death and edema formation remains unclear. Vascular endothelial growth factor (VEGF) has been suggested as a new therapeutic mediator in ischemic diseases because of its angiogenic and neuroprotective effects. However, VEGF also increases vascular permeability (VP), which could increase brain edema. Therefore, the utility of VEGF in the acute stage of brain ischemia remains controversial. Regardless, recent studies have described the use of VEGF inhibitors in the treatment of cerebral edema in patients with brain cancer.³⁾ Agents that block the VEGF pathway decreased vascular permeability and cerebral edema

by restoring the abnormal tumor vasculature to a more normal state. Thus, anti-VEGF therapy may have future clinical applications in various brain diseases associated with brain edema.

We previously developed a rat model of venous infarct via occlusion of two adjacent cortical veins.^{17,20)} At this location, cerebral blood flow (CBF) in the vicinity of the occluded veins is reduced rather homogeneously, with a large penumbra, a slowly growing infarct, and delayed cell death. Therefore, this two-vein occlusion (2-VO) model seems well suited to the study of VEGF and brain edema. We recently used magnetic resonance imaging and other techniques to demonstrate that cerebral venous infarction (CVI) in the rat were followed by VEGF expression in areas of brain edema.¹²⁾ We also demonstrated that inhibition of VEGF could reduce brain edema and CVI in the acute stage in a rat 2-VO model.¹³⁾ These observations suggest that inhibition of VEGF may be a useful therapeutic strategy for brain edema and CVI in

Received February 2, 2012; Accepted March 23, 2012

the acute stage. However, VEGF is also an important angiogenesis factor, so further study is required to characterize the effect of VEGF in the context of stroke.

The present study investigated the therapeutic time window during which inhibition of VEGF can reduce CVI in a rat 2-VO model.

Materials and Methods

A total of 42 male Wistar rats (weight 230–300 g) were purchased from Animal Supply (CLEA Japan, Inc., Tokyo). After premedication with 0.5 mg atropine sulfate, chloral hydrate was injected intraperitoneally (36 mg/100 g body weight) for the induction of anesthesia. Anesthesia was maintained by further administration of chloral hydrate (36 mg/100 g body weight) given every hour through the peritoneal catheter. All animals were intubated with silicone tubing (outer diameter 2.5 mm) and artificially ventilated using a ventilator (Model 683; Harvard Apparatus, Holliston, Massachusetts, USA) during the procedures. Rectal temperature was monitored and maintained at approximately 37.0°C with a feedback heating pad (CMA 150; Carnegie Medicine AB, Stockholm, Sweden). Polyethylene catheters were placed into the tail artery and into the right femoral vein. The arterial catheter was used for continuous monitoring of the mean arterial blood pressure (MABP) using a pressure transducer (Polygraph system RM-600; Nihon Kohden, Tokyo), and a blood gas analyzer (ABL 330; Radiometer, Copenhagen, Denmark) was used to measure blood gases (PaO₂, PaCO₂, pH) in the arterial blood. The venous catheter was used to administer fluid and drugs.

Rats were mounted on a stereotactic frame (SR-6; Narishige Inc., Tokyo), and a 1.5-cm midline skin incision and a cranial window (4.5 mm × 6 mm) was made over the left parietal region using a high-speed drill. This procedure was performed under an operating microscope (Zeiss, Wetzlar, Germany). A continuous flow of physiological saline cooled the drill tip during this procedure. The dura was left intact, and the left parietal cortex was exposed.¹⁸⁾ Two adjacent cortical veins were occluded by the photochemical thrombotic technique using Rose Bengal dye and fiberoptic illumination as described previously.^{16,17,20)} In the sham-operated group, the brains of the control animals appeared completely normal, both macroscopically and histopathologically (data not shown). This animal study was conducted in accordance with the guidelines approved at the 80th General Assembly of the Japan Science Council (1980).

The 42 rats were randomly assigned to one of four

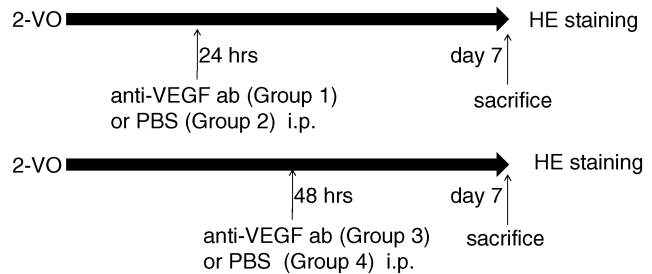


Fig. 1 Schematic representing the experimental design and experimental groups. anti-VEGF ab: anti-vascular endothelial growth factor antibody, HE: hematoxylin and eosin, i.p.: intraperitoneal, PBS: phosphate-buffered saline, 2-VO: two-vein occlusion.

groups. Group 1 was treated with a VEGF antagonist (neutralizing antibody against VEGF in phosphate-buffered saline [PBS], 2 mg/kg, rabbit polyclonal antibody RB-222 [NeoMarkers, Inc., Thermo Fisher Scientific, Kalamazoo, Michigan, USA])^{2,11)} at 24 hours after 2-VO ($n = 11$). Group 2 was treated with PBS at 24 hours after 2-VO ($n = 11$). Group 3 was treated with a VEGF antagonist at 48 hours after 2-VO ($n = 10$). Group 4 was treated with PBS at 48 hours after 2-VO ($n = 10$). All rats received single bolus intraperitoneal injection of either VEGF antagonist or PBS. After confirmation of vein occlusion, the rats were returned to individual cages and had free access to food and water. Schematics of the experimental design and experimental groups are provided in Fig. 1. Timing of injection was based on a previous report that expression of VEGF was strongly up-regulated in the ischemic penumbra at 24 hours after ischemic insult.¹⁵⁾

Seven days after surgery, the rats were sacrificed under chloral hydrate anesthesia by intracardiac perfusion with 200 ml of 0.9% NaCl. The brain was carefully removed from the skull, fixed in 10% buffered formaldehyde solution for 2 days, and then cut into several 2-mm thick coronal sections using a brain slicer. All blocks were then embedded in paraffin. One 10- μ m thick section was taken at the center of the visible infarct using a microtome and was stained with hematoxylin and eosin (HE) to measure the areas of infarct and noninfarct. The ratio of infarct area to the area of the contralateral hemisphere was determined for each coronal section. Morphometric evaluations of lesion size were analyzed using NIH Scion Image software (Scion Corp., Fredrick, Maryland, USA). The investigator was unaware of the treatment group until after histological analysis.

All data are expressed as means \pm standard error of the mean. Statistical significance was concluded

Table 1 Physiological variables before and after venous occlusion

	MABP (mmHg)	pH	PO ₂ (mmHg)	PCO ₂ (mmHg)
Group 1				
before 2-VO	93.9 ± 1.9	7.384 ± 0.01	169.1 ± 5.3	38.7 ± 0.4
after 2-VO	92.0 ± 1.7	7.375 ± 0.01	157.2 ± 4.0	37.7 ± 0.5
Group 2				
before 2-VO	92.6 ± 1.2	7.385 ± 0.01	165.7 ± 7.9	37.6 ± 0.7
after 2-VO	91.3 ± 1.0	7.377 ± 0.01	169.1 ± 6.0	36.1 ± 0.7
Group 3				
before 2-VO	94.6 ± 1.3	7.388 ± 0.01	163.1 ± 5.0	37.0 ± 0.7
after 2-VO	93.3 ± 1.2	7.384 ± 0.01	160.5 ± 5.0	37.9 ± 0.7
Group 4				
before 2-VO	93.6 ± 1.4	7.393 ± 0.01	161.6 ± 4.2	37.7 ± 0.6
after 2-VO	93.0 ± 1.2	7.385 ± 0.01	162.3 ± 4.6	37.6 ± 0.4

Data are expressed as means ± standard error of the mean. There are no statistically significant differences in any physiological variable between the 4 groups. MABP: mean arterial blood pressure, 2-VO: two-vein occlusion.

at an error probability of $p < 0.05$. All statistical comparisons were performed using Sigma-Stat software (Jandel Scientific, Erkrath, Germany).

Results

No significant differences were observed in physiological parameters (blood PaO₂ and PaCO₂, MABP) before and after venous occlusion or between the four groups (Table 1). There were no deaths or any obvious focal neurological symptoms in any of the animals after either cortical vein occlusion.

Necrotic neurons were identified by light microscopy as exhibiting one or more of the following changes: pyknosis, karyorrhexis, karyolysis, cytoplasmic eosinophilia, or loss of hematoxylin staining. The infarct zone was well demarcated and displayed pancellular necrosis as well as dense areas of eosinophilic shrunken neurons along the edges of the infarct. An infarct area had developed in the cortex and was wedge-shaped with the apex in a deeper cortical layer in all 42 rats.

The ischemic damage in Group 1 consisted of a small infarction area, as characterized by HE staining under low magnification (Fig. 2A). In contrast, the ischemic damage in Group 2 appeared as a large eosinophilic area, extending from near the superior sagittal sinus to the lateral side (Fig. 2B). The ratio of infarction area was significantly smaller in Group 1 than in Group 2 (0.0076 ± 0.0012 vs. 0.0157 ± 0.0019 , $p < 0.05$) (Fig. 3). Dilated spaces surrounding the capillaries around the infarction were prevalent in Group 2, whereas only a few dilated spaces surrounded capillaries around the infarction in Group 1 (Fig. 2C, D).

Typical ischemic lesions with HE staining in

Groups 3 and 4 are shown in Fig. 2E–H. Under low magnification, there was no difference in infarction size and shape between the two groups (Fig. 2E, F). The ratio of infarct area was also similar when comparing Groups 3 and 4 (0.0133 ± 0.0010 vs. 0.0128 ± 0.0016), but Groups 3 and 4 had significantly larger venous infarctions compared with Group 1 ($p < 0.05$) (Fig. 3). Dilated spaces surrounding the capillaries around the infarction were prevalent in both groups (Fig. 2G, H).

Discussion

The present study demonstrated that administration of VEGF antagonist at 24 hours after 2-VO attenuated CVI, whereas administration of VEGF antagonist at 48 hours had no apparent effect. Several studies have described the beneficial effects of VEGF on brain ischemia in vivo⁶⁾ and in vitro.⁷⁾ For example, VEGF can markedly enhance angiogenesis in the ischemic brain,⁴⁾ suppress the cell death pathway due to its direct neuroprotective action,²⁸⁾ and reduce neurological deficits during stroke recovery.^{5,25)} These effects may be useful to prevent stroke in patients with repeated transient ischemic attacks. However, there are several concerns regarding the use of VEGF therapy for acute brain ischemia because VEGF is also a potent VP factor. Indeed, previous studies reported that VEGF exacerbated VP and promoted ischemic cell damage.²⁹⁾ Specifically, early (1 hour) VEGF treatment promoted brain edema, hemorrhagic transformation of the infarct, and spread of the ischemic lesion in focal cerebral ischemia.²⁹⁾ Furthermore, in ischemic animals, early administration of VEGF leads to blood-brain barrier (BBB) permeability as well as to

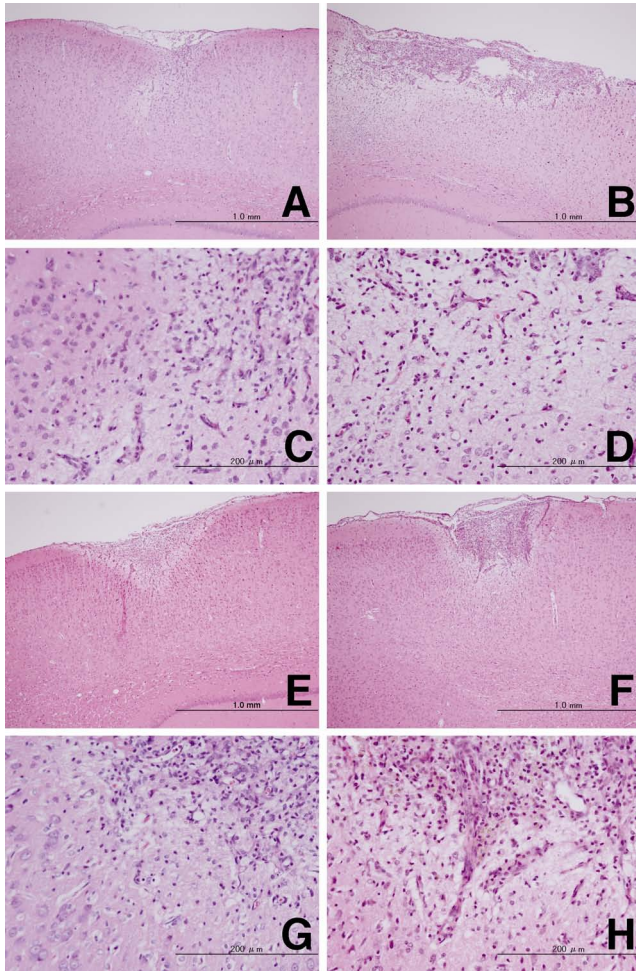


Fig. 2 Representative photomicrographs of cerebral coronal sections stained with hematoxylin and eosin from each group. All rats had local infarctions in the cortex near the superior sagittal sinus. Twenty-four hours after two-vein occlusion (2-VO), the rat treated with vascular endothelial growth factor (VEGF) antagonist (A) had a smaller infarction than the rat treated with phosphate-buffered saline (PBS) (B). Original magnification $\times 40$. Forty-eight hours after 2-VO, infarct lesion size was similar in the VEGF antagonist-treated rat (E) and PBS-treated rat (F). Original magnification $\times 40$. Higher magnification revealed inflammatory cell infiltration, cavitation, and shrinkage of nuclei in the infarct area in VEGF antagonist-treated (C, G) and PBS-treated rats (D, H) at 24 (C, D) or 48 hours after 2-VO (G, H). Original magnification $\times 200$.

induction of matrix metalloproteinase-9 activity,²⁶⁾ and early increased production of VEGF is deleterious, primarily due to BBB disruption and neuronal cell death.²²⁾ These findings suggest that VEGF can enhance cerebral microvascular perfusion as well as increase BBB leakage in the ischemic brain. However, our previous study provided evidence that

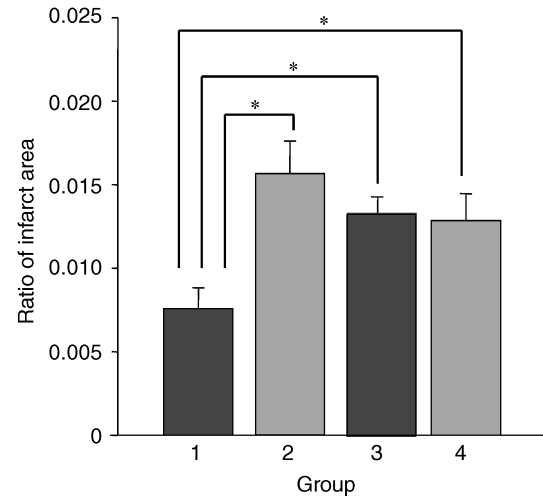


Fig. 3 Comparisons of ratio of infarct area to the contralateral hemispheric area. Group 1 (treated with vascular endothelial growth factor [VEGF] antagonist at 24 hours after two-vein occlusion) has significantly smaller venous infarctions compared with Group 2 (treated with phosphate-buffered saline [PBS] at 24 hours), Group 3 (treated with VEGF antagonist at 48 hours), and Group 4 (treated with PBS at 48 hours) (* $p < 0.05$). In contrast, there is no significant difference between Group 2, Group 3, and Group 4.

administration of VEGF antagonists immediately after 2-VO resulted in reduced brain edema and CVI.¹³⁾ Therefore, this study investigated whether there was a therapeutic window for VEGF antagonist therapy in the acute stage using a model of venous ischemia in rats.

Occlusion of two cortical veins results in widespread reduction of CBF^{17,20)} and the development of a small infarct that is approximately one-thirtieth the size of infarcts that develop after middle cerebral artery occlusion. Furthermore, the progress of flow reduction and infarct development in the 2-VO model is slower than that in arterial ischemia.¹⁹⁾ CBF mapping in the drainage area of the two occluded veins showed comparably large low-flow areas, whereas no-flow areas were barely detectable in the acute phase.¹⁷⁾ Therefore, the pathophysiologic significance of the neurotoxic mediators induced/released by venous ischemia was studied in this model. Previous studies have found that cytotoxic and vasogenic brain edema is consistently associated with acute CVI.²³⁾ This large low-flow area following CVI results not only in angiogenesis but also in increased VP, so edema formation is probably activated by the induction of VEGF expression. Therefore, we suggest that the present animal model was suitable for the evaluation of the relationship be-

tween VEGF and brain edema.

Brain edema can be classified into two basic types: cytotoxic and vasogenic.¹⁴⁾ Cytotoxic edema represents a shift of water from the extracellular to intracellular compartments without disruption of the BBB, whereas vasogenic brain edema primarily results from the disruption of the BBB and subsequent accumulation of water in the extracellular space. Vasogenic brain edema occurs during the late stage after infarction resulting from cerebral ischemia. Numerous biochemical mediators of vascular permeability have been proposed, but there are no therapies that are used to specifically modulate cerebrovascular permeability. Mannitol is the most extensively studied agent with regard to reducing ischemic brain edema, but this agent has several notable adverse effects that limit its optimal use.^{9,21)} The present study demonstrated that administration of VEGF antagonist during the acute state of ischemia in a rat 2-VO model resulted in attenuation of CVI. This is consistent with studies that have observed that expression of VEGF was strongly up-regulated in the ischemic penumbra at times 6 and 24 hours after ischemic insult.¹⁵⁾ In combination, these data suggest that VEGF antagonists may provide protection against brain edema during the acute stage of ischemia.

Previous studies in arterial ischemia models have reported that VEGF inhibition before and after ischemia results in reduced edema formation.²⁷⁾ The present study showed that administration of anti-VEGF at 24 hours after 2-VO reduced CVI, possibly by inhibiting vasogenic edema. However, use of VEGF antagonists at a later stage after vein occlusion did not result in infarct reduction. VEGF has neurotrophic effects on cultured ganglion cell²⁴⁾ and hippocampal neurons⁷⁾ and inhibition of endothelial cell apoptosis.¹⁾ Therefore, delayed application of VEGF antagonists may suppress a natural VEGF neuroprotective effect independent of its angiogenic action.

CVI generally develops much more slowly than arterial stroke. Furthermore, areas with moderate reduction of CBF causing a penumbra-like area surrounding a core infarct in CVI are wider than in those seen with arterial stroke. Therefore, the therapeutic window is much wider in CVI, and neuroprotective candidates are likely more effective for CVI in humans compared with their efficacy in arterial infarct. These and other data suggest that VEGF inhibitors may be effective in the prevention and treatment of hypoxia-induced cerebral edema.⁸⁾

Early single intracerebroventricular injection of VEGF protects the brain against ischemia without adversely affecting BBB permeability, which sug-

gests that exposure to VEGF from the vascular luminal side is required for BBB breakdown.¹⁰⁾ A greater understanding of the mechanisms of different routes of administration may help overcome the negative impacts of VEGF on BBB permeability.

This study demonstrated that administration of VEGF antagonist at 24 hours after 2-VO attenuated CVI, whereas administration of VEGF antagonist at 48 hours had no apparent effect. Thus, VEGF inhibition represents a potential therapeutic strategy to reduce brain edema and CVI in the acute stage. Further study to delineate the mode of administration and precise therapeutic time window for anti-VEGF therapy in the context of stroke is required.

Conflicts of Interest Disclosure

The authors have no personal financial or institutional interest in any of the drugs, materials, or devices in the article. All authors who are members of The Japan Neurosurgical Society (JNS) have registered online Self-reported COI Disclosure Statement Forms through the website for JNS members.

References

- 1) Alon T, Hemo I, Itin A, Pe'er J, Stone J, Keshet E: Vascular endothelial growth factor acts as a survival factor for newly formed retinal vessels and has implications for retinopathy of prematurity. *Nat Med* 1: 1024-1028, 1995
- 2) Ferrara N, Davis-Smyth T: The biology of vascular endothelial growth factor. *Endocr Rev* 18: 4-25, 1997
- 3) Gerstner ER, Duda DG, di Tomaso E, Ryg PA, Loeffler JS, Sorensen AG, Ivy P, Jain RK, Batchelor TT: VEGF inhibitors in the treatment of cerebral edema in patients with brain cancer. *Nat Rev Clin Oncol* 6: 229-236, 2009
- 4) Hai J, Li ST, Lin Q, Pan QG, Gao F, Ding MX: Vascular endothelial growth factor expression and angiogenesis induced by chronic cerebral hypoperfusion in rat brain. *Neurosurgery* 53: 963-972, 2003
- 5) Han MK, Kim M, Bae SY, Kang L, Han SY, Lee YS, Rha JH, Kim SU, Roh JK: VEGF protects human cerebral hybrid neurons from in vitro ischemia. *Neuroreport* 15: 847-850, 2004
- 6) Hayashi T, Abe K, Itoyama Y: Reduction of ischemic damage by application of vascular endothelial growth factor in rat brain after transient ischemia. *J Cereb Blood Flow Metab* 18: 887-895, 1998
- 7) Jin KL, Mao XO, Greenberg DA: Vascular endothelial growth factor: direct neuroprotective effect in in vitro ischemia. *Proc Natl Acad Sci U S A* 97: 10242-10247, 2000
- 8) Josko J, Knefel K: The role of vascular endothelial growth factor in cerebral oedema formation. *Folia Neuropathol* 41: 161-166, 2003

- 9) Kaufmann AM, Cardoso ER: Aggravation of vasogenic cerebral edema by multiple-dose mannitol. *J Neurosurg* 77: 584-589, 1992
- 10) Kaya D, Gursoy-Ozdemir Y, Yemisci M, Tuncer N, Aktan S, Dalkara T: VEGF protects brain against focal ischemia without increasing blood-brain permeability when administered intracerebroventricularly. *J Cereb Blood Flow Metab* 25: 1111-1118, 2005
- 11) Kim KJ, Li B, Winer J, Armanini M, Gillett N, Phillips HS, Ferrara N: Inhibition of vascular endothelial growth factor-induced angiogenesis suppresses tumour growth in vivo. *Nature* 362: 841-844, 1993
- 12) Kimura R, Nakase H, Sakaki T, Taoka T, Tsuji T: Vasogenic edema and VEGF expression in a rat two-vein occlusion model. *Acta Neurochir Suppl* 86: 213-217, 2003
- 13) Kimura R, Nakase H, Tamaki R, Sakaki T: Vascular endothelial growth factor antagonist reduces brain edema formation and venous infarction. *Stroke* 36: 1259-1263, 2005
- 14) Klatzo I: Presidential address. Neuropathological aspects of brain edema. *J Neuropathol Exp Neurol* 26: 1-14, 1967
- 15) Marti HJ, Bernaudin M, Bellail A, Schoch H, Euler M, Petit E, Risau W: Hypoxia-induced vascular endothelial growth factor expression precedes neovascularization after cerebral ischemia. *Am J Pathol* 156: 965-976, 2000
- 16) Nakagawa I, Alessandri B, Heimann A, Kempfski O: MitoKATP-channel opener protects against neuronal death in rat venous ischemia. *Neurosurgery* 57: 334-340, 2005
- 17) Nakase H, Heimann A, Kempfski O: Local cerebral blood flow in a rat cortical vein occlusion model. *J Cereb Blood Flow Metab* 16: 720-728, 1996
- 18) Nakase H, Kakizaki T, Miyamoto K, Hiramatsu K, Sakaki T: Use of local cerebral blood flow monitoring to predict brain damage after disturbance to the venous circulation: cortical vein occlusion model by photochemical dye. *Neurosurgery* 37: 280-286, 1995
- 19) Nakase H, Kempfski OS, Heimann A, Takeshima T, Tintera J: Microcirculation after cerebral venous occlusions as assessed by laser Doppler scanning. *J Neurosurg* 87: 307-314, 1997
- 20) Otsuka H, Ueda K, Heimann A, Kempfski O: Effects of cortical spreading depression on cortical blood flow, impedance, DC potential, and infarct size in a rat venous infarct model. *Exp Neurol* 162: 201-214, 2000
- 21) Reichenthal E, Kaspi T, Cohen ML, Shevach I, Shalmon E, Bar-Ziv Y, Feldman Z, Zucker G: The ambivalent effects of early and late administration of mannitol in cold-induced brain oedema. *Acta Neurochir Suppl (Wien)* 51: 110-112, 1990
- 22) Rite I, Machado A, Cano J, Venero JL: Blood-brain barrier disruption induces in vivo degeneration of nigral dopaminergic neurons. *J Neurochem* 101: 1567-1582, 2007
- 23) Rother J, Waggie K, van Bruggen N, de Crespigny AJ, Moseley ME: Experimental cerebral venous thrombosis: evaluation using magnetic resonance imaging. *J Cereb Blood Flow Metab* 16: 1353-1361, 1996
- 24) Sondell M, Lundborg G, Kanje M: Vascular endothelial growth factor has neurotrophic activity and stimulates axonal outgrowth, enhancing cell survival and Schwann cell proliferation in the peripheral nervous system. *J Neurosci* 19: 5731-5740, 1999
- 25) Sun Y, Jin K, Xie L, Childs J, Mao XO, Logvinova A, Greenberg DA: VEGF-induced neuroprotection, neurogenesis, and angiogenesis after focal cerebral ischemia. *J Clin Invest* 111: 1843-1851, 2003
- 26) Valable S, Montaner J, Bellail A, Berezowski V, Brillault J, Cecchelli R, Divoux D, Mackenzie ET, Bernaudin M, Roussel S, Petit E: VEGF-induced BBB permeability is associated with an MMP-9 activity increase in cerebral ischemia: both effects decreased by Ang-1. *J Cereb Blood Flow Metab* 25: 1491-1504, 2005
- 27) van Bruggen N, Thibodeaux H, Palmer JT, Lee WP, Fu L, Cairns B, Tumas D, Gerlai R, Williams SP, van Lookeren Campagne M, Ferrara N: VEGF antagonism reduces edema formation and tissue damage after ischemia/reperfusion injury in the mouse brain. *J Clin Invest* 104: 1613-1620, 1999
- 28) Wang Y, Kilic E, Kilic U, Weber B, Bassetti CL, Marti HH, Hermann DM: VEGF overexpression induces post-ischaemic neuroprotection, but facilitates haemodynamic steal phenomena. *Brain* 128: 52-63, 2005
- 29) Zhang ZG, Zhang L, Jiang Q, Zhang R, Davies K, Powers C, Bruggen Nv, Chopp M: VEGF enhances angiogenesis and promotes blood-brain barrier leakage in the ischemic brain. *J Clin Invest* 106: 829-838, 2000

Address reprint requests to: Ichiro Nakagawa, MD, Department of Neurosurgery, Nara Medical University, 840 Shijo-cho, Kashihara, Nara 634-0813, Japan.
e-mail: nakagawa@naramed-u.ac.jp