

Title: Gelatin Sealing Sheet for Arterial Hemostasis and Anti-adhesion in Vascular Surgery: a Dog Model Study

Authors: Yinghao Hu [1], Keigo Yamashita, MD* [1], Nobuoki Tabayashi, MD [1], Takehisa Abe, MD [1], Yoshihiro Hayata, MD [1], Tomoaki Hirose, MD [1], Shun Hiraga, MD [1], Takashi Tojo, MD [1], Shuko Suzuki, PhD [2,3], Yoshito Ikada, PhD [2,4], and Shigeki Taniguchi, MD [1].

Affiliation: [1] Department of Thoracic and Cardiovascular Surgery and [2] Biomedical Engineering, School of Medicine, Nara Medical University, 840 Shijo-cho, Kashihara city, Nara, 634-8521, JAPAN

[3] Queensland Eye Institute, 140 Melbourne street, South Brisbane, QLD 4101, AUSTRALIA

[4] Emeritus Professor of Kyoto University, 53 Kawara-cho Shogoin, Sakyo-ku, Kyoto 606-8507, JAPAN

* Corresponding author (Keigo Yamashita)

Telephone number: +81-744-22-3051

Fax number: +81-744-24-8040

E-mail address: ke-igo@umin.ac.jp

Abstract

BACKGROUND: The bilayer gelatin sealing sheet was developed as a safe, effective, easy-to-handle and low-cost hemostatic agent.

OBJECTIVE: To examine the feasibility of gelatin sealing sheets using a canine arterial hemorrhage model.

METHODS: *In vivo* degradation of gelatin sealing sheets was examined by implanting subcutaneously in rats. For the hemostatic and anti-adhesion efficacy investigations, femoral arteries of dogs were pricked with syringe needle to make a small hole, and a gelatin (i.e. experimental group) or fibrin glue sealing sheet (i.e. control group) was applied on the hole to stop bleeding (n = 8). After discontinuation of the bleeding, the skin incisions were closed and re-examined 4 weeks postoperatively.

RESULTS: From the degradation study, 4 h thermally treated gelatin sheet which degraded within 3 weeks *in vivo* was chosen for the further hemostatic study. In all cases of gelatin and fibrin glue sealing sheets, bleeding from the needle hole on canine femoral arteries was effectively stopped. Postoperative adhesions and inflammation at the site in the experimental group were significantly less than those in the control group ($P < 0.01$ for adhesion scores).

CONCLUSIONS: The gelatin sealing sheet was found to be as effective as the fibrin glue sealing sheet as a surgical hemostatic agent, and more effective in preventing postoperative adhesions.

Keywords: gelatin, fibrin glue, surgical sealant, anti-adhesion, postoperative adhesions

1. Introduction

In the field of cardiovascular surgery, surgeons are often faced with intractable surgical bleeding because of systemic heparinization or prolonged extracorporeal circulation. However, it may be difficult to make some surgical repair in cases of bleeding from a deep surgical site, weak tissues, or needle holes. In such cases, surgical sealants and hemostatic agents have often been applied to aid to cease hemorrhage either mechanically when surgeons compress the bleeding points (i.e. passive hemostatic agents), or by augmenting the body's response to coagulation (i.e. active hemostatic agents). Currently various biodegradable hemostatic agents are commercially available including Gelfoam (gelatin, Pfizer), Abiten (collagen, Bard), Surgicel (oxidized cellulose, Ethicon), HemCon (chitosan, HemCon medical), TachoComb/TachoSil (collagen sponge with fibrin glue components, Nycomed Arzneimittel), and FloSeal (gelatin and thrombin, Baxter). Fibrin glue is another product that has been frequently used for controlling hemorrhage, but it is not applicable when compression is required.

Passive hemostatic agents, such as gelatin sponges and sheets, provide physical structures around the bleeding sites for the platelets to aggregate and form clots. They can absorb fluid up to several times of their own weight and are useful in the situation of heavier bleeding. However there are some disadvantages, such as weak adherence to wet tissues, complications from the expanded materials pressing nerves in surrounding tissues against hard tissue, confusions of the presence of passive hemostatic agents in subsequent diagnostic images with a tumor or abscess, and prolonged residual products casting foreign body reaction that lead to granuloma formation [1]. Difficulties of handling of gelatin-based products have been reported since these materials tend to stick to surgical

instruments when wet [1].

On the other hand, active hemostatic substances contain agents, such as thrombin, that actively involved in the clot formation at the bleeding site. The fibrin glue sealing sheet (i.e. TachoComb) is a combination of active and passive agents, that consists of equine collagen fleece with one surface coated with fibrin components (human fibrinogen, bovine thrombin and bovine aprotinin). When the coating of collagen fleece comes in contact with fluids, the components dissolve and diffuse into the cavities and begin to react to form a fibrin gel. The collagen fleece helps to tamponade the wounds, and keeps the coagulation components at the bleeding site. It requires 3-5 min of pressing until the area is sealed. Unlike the liquid-type fibrin glues that require tedious preparation, the fibrin glue sealing sheet is ready to use, and has a high adhesive strength [2]. The sheets have been shown to stop bleeding effectively from various organs, and have frequently been used in many clinical applications [3-6]. Despite the efficacy of the fibrin glue sealing sheet, plasma derivatives have a risk of virus transmission, and are high in cost. The collagen product is also known to express some antigenicity in physiological conditions. Moreover, anti-adhesive effect of this material is unclear. Hence, development of safe, effective and low-cost hemostatic agents is still on going.

In this study, gelatin was chosen as the hemostatic sealing sheet material. Gelatin has been widely used in medical applications and its biocompatibility is well documented. Gelatin has several advantages compared to collagen such as low-in-cost and non-antigenic. It is also practically more convenient than native collagen which is very difficult to prepare a concentrated solution. Although gelatin is soluble in warm water, various crosslinking

methods are available and its *in vivo* degradation can be finely tuned by the crosslinking density. A number of gelatin-based sponges have been developed as hemostatic agents [7-10] and wound dressings [11-13]. Porous gelatin sponges can be prepared by freeze-drying or foaming the gelatin solution by beating or agitating with a propeller, mixer, or homogenizer. Depending on processing techniques and conditions, properties of sponges, such as pore size and wall-thickness, can be altered. Hajosch *et al.* recently developed porous gelatin sponge with the nano-rough surface by air-bubbling the gelatin solution in the presence of a chemical crosslinker followed by drying and mechanical processing [8]. The resulting material showed rapid human blood absorption *in vitro* and excellent hemostatic performance *in vivo*.

For this research, thermally crosslinked bilayer gelatin sealing sheet was developed which consists of a foam layer and a thin film layer for improved handling of the hemostatic agent and anti-adhesive property. The foam layer is used to provide a physical structure for blood coagulation. It is made by lyophilization of 1 % gelatin solution and is soft and adheres well to tissue surfaces. The film layer is approximately 20 μm thickness and flexible. This film layer has two purposes: stopping blood permeation to prevent sticking to surgeon's gloves during compression, and preventing tissue adhesions. In this study, application of the gelatin sealing sheet in vascular surgery was investigated. We first evaluated *in vivo* degradation of gelatin sealing sheets by subcutaneous implantation in rats, and the optimum thermal treatment time for crosslinking was investigated. Then, the effectiveness of gelatin sealing sheet for hemostasis and preventing tissue adhesion in comparison with the fibrin glue sealing sheet was investigated using a canine arterial hemorrhage model.

2. Materials and Methods

2.1. Materials

Medical grade gelatin extracted from porcine skin with an isoelectric point of 5 (Medigelatin[®]) was purchased from Nippi Co. (Tokyo, Japan). Fibrin glue sealing sheets (TachoComb Tissue Sealing Sheet[®]) were purchased from CSL Behring Inc. (Tokyo, Japan). Sodium pentobarbital (Somnopenyl[®]) was purchased from Kyoritsu Seiyaku (Tokyo, Japan). All other reagents and surgical materials were purchased from Wakenyaku Co. Ltd. (Osaka, Japan). Doubly distilled water was used for any preparation.

Female Wistar ST rats (8 weeks old, weighing approximately 200 g) were purchased from Japan SLC, Inc. (Kyoto) for the *in vivo* degradation study. To test the hemostasis and anti-adhesion effects of gelatin sheets, healthy female beagles (11-13 months old, 9-11 kg) were purchased from Shimizu Laboratory Animal Supply Co. (Kyoto, Japan). Animal housing, human care, and surgical procedures were performed in accordance with the institutional guidelines of the animal research committees of Nara Medical University.

2.2. Preparation of gelatin sealing sheets

The bilayer gelatin matrix, consisting of a cast film layer and a foam layer, was prepared as follows and illustrated in Figure 1:

2.2.1 Preparation of a film layer

After gelatin was dissolved in distilled water to a final concentration of 3.0 wt%, the solution (13.5 mL) was cast onto a polystyrene dish (Corning suspension culture dishes,

measuring 150 mm in diameter and 25 mm in height, Cardinal Health Inc., Dublin, Ohio, USA), and allowed to dry overnight in a clean bench with constant air flow at room temperature, yielding a film layer of approximately 20 μm in thickness. Then the upper side of the film layer was exposed to UV light at a distance of 25 mm from a UV lamp (GL-15, NEC Lighting, Ltd., Tokyo, Japan) for 5 min.

2.2.2 Preparation of a foam layer

Gelatin solution (1.0 %, 70.0 mL) was cast onto the film layer and allowed to remain at room temperature for 10 min to merge the solution into the film layer. Then these were frozen at -80°C for longer than 10 min using a deep freezer (MDF-394, Panasonic Healthcare Co., Tokyo, Japan) and lyophilized with a vacuum freezing dryer (DRZ 350 WA, ADVANTEC, Tokyo, Japan) for 24 hr. The bilayer gelatin matrix was thermally crosslinked using a vacuum oven (DP43, YAMATO, Tokyo, Japan) at 140°C for 4 h, unless otherwise stated.

All gelatin sealing sheets used for the animal experiments were sterilized by ethylene oxide gas (0.43 g/L for 4 h at 40°C).

2.3. Scanning electron microscopy (SEM)

The foam morphology of the bilayer sheet, which were gold coated, were visualized using HITACHI Miniscope TM-1000 (Hitachi High-Tech. Corp., Tokyo, Japan), and the pore size was examined and expressed as mean \pm SD ($n = 10$).

2.4. *In vivo* degradation in rats

For the degradation study, gelatin sheets were thermally crosslinked at 140°C for 2, 3, or 4 h. Female Wistar ST rats were housed at room temperature and given the standard rat chow. After 1-2 weeks, intraperitoneal administration of sodium pentobarbital (30 mg/kg body weight) was applied to each rat for general anesthesia. The back area was shaved and treated with 70 % ethyl alcohol before creating two incisions of about 1 cm in length. Known weights of sterilized gelatin sheets were subcutaneously implanted and incisions were stitched with 3-0 nylon monofilament. After 1, 2, 4, 7, and 14 days post-operatively, the rats were euthanized with overdose of sodium pentobarbital (300 mg/kg) and the sheets were carefully removed and washed with cold water, followed by drying. The weight of dried sheets was measured, and the *in vivo* degradation was expressed as percentage of the remaining dry weight. Each experiment was triplicated and the results were expressed as mean \pm SE.

2.5. Canine arterial hemorrhage model

2.5.1 Surgical procedure

Two surgical sealants were used to perform a randomized trial on dogs: gelatin sealing sheets (with thickness of 3 mm, i.e. the experimental group) and fibrin glue sealing sheets (i.e. the control group). Sixteen dogs were randomly divided into the experimental and control groups. Sodium pentobarbital (25 mg/kg) was applied to each dog by intravenous injection for general anesthesia. After shaving the groin area, Hibitane solution was applied to disinfect. All surgical instruments, gauze, and embedding material were sterilized in advance. Operation was performed in an aseptic fashion. An incision was created to expose the femoral artery, and heparin (0.8-0.9 mL) was administered intravenously. Five minutes after the heparin administration, the blood flow was cut off

by clamping two places of femoral artery with hemostatic forceps, and the femoral artery was pricked with a syringe needle of gauge size 23 to make a bleeding hole. Then blood from the needle hole was carefully wiped off with gauze. For hemostasis, gelatin and fibrin glue sealing sheets were applied to the experimental and the control groups, respectively. The sealing sheets (1.5×2 cm²) were wrapped around the artery and compressed with fingers for 5 min. When the sheets effectively stopped bleeding on the femoral arteries, the skin incisions were closed with simple interrupted stitches with 1-0 nylon suture, leaving the hemostatic agent on the femoral arteries.

2.5.2 Evaluation of adhesion

All dogs were euthanized with overdose anesthesia (pentobarbital 250 mg/kg) 4 weeks after the first operation, and their femoral arteries were examined for postoperative adhesions. The adhesion area and force required to separate the adhesion were scored in a blinded manner according to the method of Zuhlke et al. as follows [14, 15].

The adhesion area

0: No adhesions

1: Adhesions with 1~25 % of the surgical field area

2: Adhesions with 26~50 % of the surgical field area

3: Adhesions with 51~75 % of the surgical field area

4: Adhesions with 76~100 % of the surgical field area

The adhesion strength

0: No adhesions

- 1: Filmy, fibrin adhesions, easily removed by blunt dissection (mild)
- 2: Fibrous adhesions, easily dissected (moderate)
- 3: Thick fibrous adhesions, dissectable (severe)
- 4: Thick fibrous adhesions, not dissectable without damage to the adherent tissue (very severe)

For the histological examination, the sites were harvested and fixed in 4 % paraformaldehyde phosphate buffer solution followed by embedded in paraffin. The thin sections were generated and examined after staining with hematoxylin-eosin.

2.5.3 Statistical analysis

Quantitative results from canine models were obtained from eight samples. Results were expressed as mean \pm SD. Statistical analysis was carried out using unpaired Student's t-test and Mann-Whitney u-test. A value of $P < 0.05$ was considered to be statistically significant.

3. Results

3.1. Gelatin sealing sheet and its *in vivo* degradation

Figure 2(a) shows a photograph of a gelatin sealing sheet, which consists of a film layer and a foam layer, in a dry state. From SEM images of the foam layers (Figure 2(b)), the pore size was found to be $98.0 \pm 23.8 \mu\text{m}$. The average density of the gelatin sealing sheet was 0.017 g/cm^3 . The crosslinking of gelatin sheets was performed by treating them at $140 \text{ }^\circ\text{C}$ under high vacuum at various duration of time. These sheets were subcutaneously implanted into the back of rats for different periods, and *in vivo* degradation was

expressed as percentages of the remaining dried sheets (Figure 3). The degradation rate decreased with the increasing thermal treatment time. Two hour and 3 h thermal treated sheets were not found after 4 days and 2 weeks implantation, respectively. About 20% of 4 h thermal treated sheet were present after 2 weeks, and it would degrade completely within 3 weeks. We have chosen this sheet for further study of application in a hemostatic sheet.

3.2. Arterial hemostasis efficacies of two sealing sheets

Under anesthetic and heparinized conditions, dog's femoral artery was exposed and pricked with a 23 G needle to create a hemorrhage model. The sealing sheet was applied onto the needle hole and pressed for 5 min. The gelatin sealing sheet was flexible and easy to apply to the uneven surface. It adhered to the application site and did not attach to the surgeon's gloves after 5 min of compression. All gelatin sheets (n=8) effectively stopped bleeding from the needle holes. No bleeding was observed even 5 min after hemostasis. In addition, all fibrin glue sheets in the control group stopped bleeding from the needle holes (n=8). All 16 dogs survived the procedure.

3.3. The postoperative adhesions

During 4 weeks, no mortalities or morbidities were observed those associated with the operation or the application of either type of sheets. All dogs were euthanized with high dose of sodium pentobarbital after 4 weeks, and postoperative vascular and tissue adhesions were examined. Figure 4 shows photographs of surgical sites 4 weeks postoperatively: (a) the control group (i.e. the fibrin glue sealing sheet), and (b) the experimental group (i.e. the gelatin sealing sheet). The scores of adhesion area and

strength were evaluated by surgeons who were not involved in the operations, and are shown in Table 1. The experimental group had less and weaker adhesions than those in the control group that had severe adhesion of surrounding adipose tissues. The gelatin sealing sheets were adsorbed and not present at the site after 4 weeks. In the case of fibrin glue sealing sheets, remaining materials were unclear due to the severe adhesions.

Figure 5 shows representative images of the HE stained femoral arteries 4 weeks postoperatively: (a) the control group (i.e. the fibrin glue sealing sheet), and (b) the experimental group (i.e. the gelatin sealing sheet). The specimens from the control group showed severe inflammatory responses at the adherent tissues. Eosinophils and lymphocytes were the main cells present at the adhesion site. Some plasma cells were also detected, whereas no neutrophils were found. The presence of residual collagen fleeces was not identified by this staining method. On the other hand, the specimen from the experimental group showed no detectable inflammatory response.

4. Discussion

4.1. Surgical hemostatic agents

In this study, the commercially available fibrin glue sealing sheet (i.e. Tachocomb) was used as a control group. The fibrin glue sealing sheet is widely used in many clinical situations, and has already proved to be an effective hemostatic agent in controlling bleeding in cardiovascular surgery [16]. The manufacturer's latest version of the product (i.e. TachoSil) does not contain aprotinin which is found to be associated with risk of renal failure. In addition, human thrombin is used in this material. An animal experimental study has shown that there is no difference between TachoSil and

TachoComb for hemostatic properties [17]. However, these products have a risk of virus transmission due to plasma derivatives, and high in cost. Moreover, efficacy of the fibrin glue sealing sheet on anti-adhesion is not clear, compared with its effect of hemostasis. For the development of a new sealing sheet, we have chosen gelatin as a material, which has a long history of excellent biocompatibility.

Thermally crosslinked bilayer gelatin sealing sheet was designed to be an easy-to-handle hemostatic agent with anti-adhesion effect. Gelatin-based sealants have been created using different crosslinking agents, such as genipin [18], water-soluble carbodiimides [18,19], transglutaminase [20,21], biopolymers [22-24], and glutaraldehyde [25]. The use of chemical crosslinking agents has a risk of cytotoxicity caused by the unreacted compounds and their degradation products. It has been reported that unstable glutaraldehyde polymer released from the glutaraldehyde crosslinked material caused cytotoxicity [26]. Alternatively, gelatin can be crosslinked by UV irradiation [27] or thermal treatment [28-31]. These techniques do not require chemical agents, and hence, are safer options. In this study, we have employed UV crosslinking for the gelatin film in the first step to stabilize it before the solution for the second layer was pored on, and then thermal treatment for the bilayer matrix after a foam layer was created.

By altering the thermal treatment time, degradation rate of the gelatin material can be finely tuned. This study demonstrated *in vivo* degradation of gelatin sealing sheets with various thermal treatment times. As an anti-adhesive material, the sheet should be present to isolate the injured site from the adjacent tissues until the site heals. However, the prolonged existence of a surgical material at the injury site may induce foreign body

reaction which leads to strong connective tissue formation and adhesions. Therefore the degradation rate of the sheet is an important factor to consider. We have chosen 4 h thermally treated sheet at 140 °C under high vacuum, which degrades approximately in 3 weeks. Although it is expected that the simple arterial hemorrhage model used in this study may heal quickly, this degradation rate would suit in the real situations where injuries are more complicated.

To test the hemostasis and anti-adhesion effects of gelatin sheets, canine arterial hemorrhage models were used due to similar organ-size and handling during surgery to those of human ones compared with murine models. Canine arterial hemorrhage model was created by pricking the femoral artery with a 23 G needle after heparin was administrated. Since the diameter of the femoral artery was about 3 mm, larger diameter needles than 23 G would penetrate the artery, whereas bleeding from the needle holes created by smaller diameter than 23 G were found to be easily stopped. Both sealing sheets effectively stopped bleeding from the needle holes. For this application, both sheets were easy to use. The gelatin sealing sheet was soft and flexible to wind around the artery, and adhered well. Due to the film layer preventing blood penetration, the gelatin sealing sheet did not adhere to the surgeon's gloves.

4.2. Postoperative adhesions

Postoperative adhesion is an unresolved issue in surgery and known as one of common postoperative complications in abdominal surgery, gynecology, and cardiothoracic surgery [32,33]. In cardiovascular surgery, the postoperative adhesions formed after the

operation around heart, great vessels and bypass vessels due to the prolonged operation time, hemorrhage, and infection. The adhesion will increase the risk of re-operation. The incidence of intraoperative injury on great vessels is 2-6 % because of postoperative adhesions [34]. Vlahakes reported that postoperative adhesion is one of the causes of the right ventricular failure [35]. To solve this postoperative adhesion, anti-adhesive barrier materials have been frequently used.

Several clinical and animal studies have demonstrated effectiveness of the fibrin glue sealing sheets on anti-adhesion when compared with no treatment [36-38], whereas others showed no effects [39,40]. This study showed severe adhesions in the control group in which the fibrin glue sealing sheet was applied. In contrast, anti-adhesion effect of gelatin has been reported elsewhere [25, 27-31]. A thermally treated gelatin sheet, reinforced with bioabsorbable poly(glycolic acid) mesh, exhibited reduced formation of pleural and pericardial adhesion and inflammatory reaction in a canine model [29,30].

The present study demonstrated that the gelatin sealing sheet was more effective for preventing tissue adhesion compared with the fibrin glue sealing sheet in the canine arterial hemorrhage model. Microscopic examinations revealed strong inflammatory responses at the adhesion site when the fibrin glue sealing sheet was applied, whereas no inflammation was observed for the gelatin sealing sheet group. Although we did not further examine the presence of collagen fleeces at the adhesion site, since the degradation of the fibrin glue sealing sheet is reported to be between 16 and 20 weeks from the manufacturer's information, it is possible that residual collagen fibers causing inflammatory response that led to the tissue adhesion at 4 weeks postoperatively. On the

other hand, the gelatin sealing sheet was designed to degrade in 3 weeks, and indeed, was not present 4 weeks after the initial operation. The gelatin sealing sheet may have a significant value on pericardiosymphysis and some surgical operations like percutaneous aortic valve replacement (PAVR) and percutaneous coronary intervention (PCI), where surgeons have to operate on vessels.

As this study only used a simple arterial hemorrhage model, in the future, more complicated hemorrhage models that are close to the real situations should be performed to prove the safety and efficacy of this new surgical sealing sheet. Gelatin is a promising biodegradable material to be studied in more details, as this material can be processed easily into various shapes including films, sponges, microspheres and gels, and the degradation rate can be finely tuned by the choice of crosslinking technologies. Furthermore, it has other potentials such as to load anti-adhesion drugs and agents. It is also necessary to compare the effectiveness of the gelatin sealing sheet with other commercially available hemostatic agents and anti-adhesive products.

5. Conclusions

The gelatin sealing sheet has high efficiency as a surgical hemostatic agent on the femoral artery of dogs, similar to the fibrin glue sealing sheet. However, the gelatin sealing sheet is more effective in preventing dog postoperative vascular adhesions than the fibrin glue sealing sheet.

6. References

1. Samudrala, S. Topical hemostatic agents in surgery: a surgeon's perspective. *Aorn J.*

2008;88(3):S2-S11

2. Carbon RT, Baar S, Kriegelstein S, Huemmer HP, Barr K, Simon S-I. Evaluating the in vivo adhesive strength of biomaterials. Biosimulator for selective leak closure. *Biomaterials*. 2003;24:1469-75

3. Agus GB, Bono AV, Mira E, Olivero S, Peilowich A, Homdrum E, Benelli C. Hemostatic efficacy and safety of TachoComb in surgery. Ready to use and rapid hemostatic agent. *Int Surg*. 1996;81(3):316-9

4. Joseph T, Adeosun A, Paes T, Bahal V. Randomized controlled trial to evaluate the efficacy of TachoComb H Patches in controlling PTFE suture-hole bleeding. *Eur J Vasc Endovasc Surg*. 2004;27(5):549-52

5. Haas H. The use of surgical patch coated with human coagulation factors in surgical routine: a multicenter postauthorization surveillance. *Clin Appl Thromb Hemost*. 2006;12(4):445-50

6. Marion Reddy AS, Reddy B, Holzer A, Saringer W, Steiger C, Matula C. Watertightness and effectiveness of a fibrin-based collagen fleece (TachoComb) in neurosurgery. *Eur Surg* 2003;35(5):278-81

7. Cenni E, Ciapetti G, Stea S, Corradini A, Carozzi F. Biocompatibility and performance in vitro of a hemostatic gelatin sponge. *J Biomater Sci Polym Ed* 2000;11(7):685-99

8. Hajosch R, Suckfuell M, Oesser S, Ahlers M, Flechsenhar K, Schlosshauer B. A novel gelatin sponge for accelerated hemostasis. *J Biomed Mater Res B Appl Biomater* 2010;94(2):372-9

9. Kabiri M, Emami SH, Rafinia M, Tahriri M. Preparation and characterization of absorbable hemostat crosslinked gelatin sponge for surgical applications. *Current Appl Phys* 2011;11:457-61

10. Imani R, Rafienia M, Emami H. Synthesis and characterization of glutaraldehyde-based crosslinked gelatin as a local hemostat sponge in surgery: an in vitro study. *Bio-Med Mater Eng* 2013;23:211
11. Ulubayram K, Cakar AN, Korkusuz P, Ertan C, Hasirci N. EGF containing gelatin-based wound dressings. *Biomaterials* 2001;22:1345
12. Choi YS, Lee SB, Hong SR, Lee YM, Song KW, Park MH. Studies on gelatin-based sponges Part III: a comparative study of cross-linked gelatin/alginate, gelatin/hyaluronate and chitosan/hyaluronate sponges and their application as a wound dressing in full-thickness skin defect of rat. *J Mater Sci Mater Med* 2001;12:67-73
13. Hong SR, Lee SJ, Shim JW, Choi YS, Lee YM, Song KW, Park MH, Nam YS, Lee SI. Study on gelatin-containing artificial skin IV: a comparative study on the effect of antibiotic and EGF on cell proliferation during epidermal healing. *Biomaterials* 2001;22:277-2783
14. Zuhlke HV, Lorenz EM, Straub EM, Savvas V. Pathophysiology and classification of adhesions. *Langenbecks Arch Chir Suppl II Verh Dtsch Ges Chir.* 1990:1009-16.
15. Lo HY, Kuo HT, Huang YY. Application of polycaprolactone as an anti-adhesion biomaterial film. *Artif Organs.* 2010;34(8):648-53.
16. Bajardi G, Pecoraro F, Mirabella D. Efficacy of TachoSil patches in controlling Dacron suture-hole bleeding after abdominal aortic aneurysm open repair. *J Cardiothorac Surg.* 2009;4:60.
17. Agger P, Langhoff J, Smerup MH, Hasenkam JM. Comparison between TachoComb and TachoSil for surgical hemostasis in arterial bleeding: an animal experimental study. *J Trauma.* 2010;68(4):838-842
18. Sung HW, Huang DM, Chang WH, Huang RN, Hsu JC. Evaluation of gelatin

- hydrogel crosslinked with various crosslinking agents as bioadhesives: in vitro study. *J Biomed Mater Res*. 1999;46(4):520-30.
19. Tomihata K, Ikada Y. Crosslinking of gelatin with carbodiimides. *Tissue Eng*. 1996;2(4):307-13.
20. Liu Y, Kopelman D, Wu LQ, Hijji K, Attar I, Preiss-Bloom O, Payne GF. Biomimetic sealant based on gelatin and microbial transglutaminase: an initial in vivo investigation. *J Biomed Mater Res B Appl Biomater*. 2009;91(1):5-16.
21. Chen T, Janjua R, McDermott MK, Bernstein SL, Steidl SM, Payne GF. Gelatin-based biomimetic tissue adhesive. Potential for retinal reattachment. *J Biomed Mater Res B Appl Biomater*. 2006;77(2):416-22.
22. Otani Y, Tabata Y, Ikada Y. A new biological glue from gelatin and poly (L-glutamic acid). *J Biomed Mater Res*. 1996;31(2):158-66.
23. Otani Y, Tabata Y, Ikada Y. Hemostatic capability of rapidly curable glues from gelatin, poly (L-glutamic acid), and carbodiimide. *Biomaterials*. 1998;19(22):2091-8.
24. Otani Y, Tabata Y, Ikada Y. Sealing effect of rapidly curable gelatin-poly (L-glutamic acid) hydrogel glue on lung air leak. *Ann Thorac Surg*. 1999;67(4):922-6.
25. Suzuki S, Ikada Y. Sealing effects of crosslinked gelatin. *J Biomater Appl*. 2013;27(7):801-10.
26. Huang-Lee L L, Cheung DT, Nimni ME. Biochemical changes and cytotoxicity associated with the degradation of polymeric glutaraldehyde derived crosslinks. *J Biomed Mater Res*. 1990;24(9):1185-1201
27. Matsuda S, Se N, Iwata H, Ikada Y, Evaluation of the antiadhesion potential of UV crosslinked gelatin films in a rat abdominal model. *Biomaterials*. 2002;23(14):2901-8.
28. Tsujimoto H, Tanzawa A, Matoba M, Hashimoto A, Suzuki S, Morita S, Ikada Y,

Hagiwara A. The anti-adhesive effect of thermally crosslinked gelatin film and its influence on the intestinal anastomosis in canine models. *J Biomed Mater Res B Appl Biomater.* 2013;101(1):99-109.

29. Yoshioka I, Saiki Y, Sakuma K, Iguchi A, Moriya T, Ikada Y, Tabayashi K. Bioabsorbable gelatin sheets latticed with polyglycolic acid can eliminate pericardial adhesion. *Ann Thorac Surg* 2007;84(3):864-70.

30. Matsumura G, Shin'Oka T, Ikada Y, Sakamoto T, Kurosawa H. Novel Anti-adhesive pericardial substitute for multistage cardiac surgery. *Asian Cardiovasc Thorac Ann* 2008;16(4):309-12.

31. Tsujimoto H, Takamori H, Tsuji M, Hayashi M, Ikeda J, Orikasa T, Torii H, Ozamoto Y, Suzuki S, Morita S, Ikada Y, Hagiwara A. Development of gelatin flakes a new type of anti-adhesive material: a preliminary study of in vivo rat adhesion models. *Surg Today.* 2014;44(2):391-4.

32. Menzies D, Ellis H. Intestinal obstruction from adhesions--how big is the problem? *Ann R Coll Surg Engl.* 1990;72(1):60-3.

33. De Wilde RL, Brölmann H, Koninckx PR, Lundorff P, Lower AM, Wattiez A, Mara M, Wallwiener M; The Anti-Adhesions in Gynecology Expert Panel (ANGEL). Prevention of adhesions in gynaecological surgery: the 2012 European field guideline. *Gynecol Surg.* 2012;9(4):365-368.

34. Duncan DA, Yaacobi Y, Goldberg EP, Mines M, O'Brien D, Congdon F, Carmichael MJ. Prevention of postoperative pericardial adhesions with hydrophilic polymer solutions. *J Surg Res.* 1988;45(1):44-9.

35. Vlahakes GJ. Right ventricular failure following cardiac surgery. *Coron Artery Dis.* 2005;16(1):27-30.

36. Osada H, Minai M, Yoshida T, Satoh K. Use of fibrin adhesive to reduce post-surgical adhesion reformation in rabbits. *J Int Med Res.* 1999;27(5):242-6
37. Osada H, Tanaka H, Fuji TK, Tsunoda I, Yoshida T, Satoh K. Clinical evaluation of a haemostatic and anti-adhesion preparation used to prevent postsurgical adhesion. *J Int Med Res.* 1999;27(5):247-52
38. Komatsu K, Fuji A, Higami T. Haemostatic fleece (TachoComb) to prevent intrapleural adhesions after thoracotomy: a rat model. *THorac Cardiovasc Surg.* 2007;55(6):385-90
39. Erb MA, Claus T, Hartrumpf M, Bachmann S, Albes JM. The use of TachoSil[®] surgical patch or fibrin glue in coronary artery surgery does not affect quality of anastomosis or provoke postoperative adhesions in pig. *Eur J Cardiothorac Surg.* 2009;36:703-7
40. Niwa D, Koide M, Fujie T, Goda N, Takeoka S. Application of nanosheets as an anti-adhesion barrier in partial hepatectomy. *J Biomed Mater Res Part B.* 2013;101B:1251-8

Table 1. The adhesion scores at 4 weeks after surgery in the canine arterial hemorrhage model

	Score (Adhesion Area)						Score (Adhesion Strength)							
	0	1	2	3	4	Mean \pm SD	<i>P</i> value	0	1	2	3	4	Mean \pm SD	<i>P</i> value
Fibrin glue sheet (<i>n</i> = 8)	0	0	2	5	1	2.88 \pm 0.64] 0.003*	0	1	2	3	2	2.75 \pm 1.04] 0.003*
Gelatin sheet (<i>n</i> = 8)	0	3	5	0	0	1.63 \pm 0.52		0	7	1	0	0	1.13 \pm 0.35	

* *P* < 0.01

Data are number of dogs.

Figure captions:

Figure 1. Preparation of gelatin sealing sheet

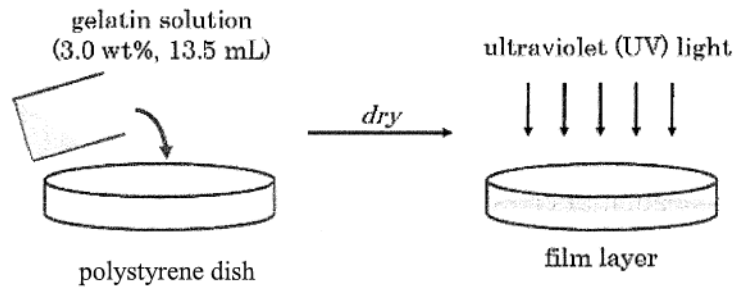
Figure 2. (a) Photograph of the bilayer gelatin sealing sheet and (b) SEM image of the foam layer

Figure 3. *In vivo* degradation of crosslinked gelatin sealing sheet with different thermal treatment time at 140°C under high vacuum. Treatment time: circle = 2 h, triangle = 3 h, and square = 4 h. Error bars indicate the standard error.

Figure 4. Photographs of femoral arteries 4 weeks after operation: (a) the control group (fibrin glue sealing sheet), and (b) the experimental group (gelatin sealing sheet)

Figure 5. Histological examination of femoral arteries 4 weeks after operation: (a) the control group (fibrin glue sealing sheet), and (b) the experimental group (gelatin sealing sheet)

Preparation of the film layer



Preparation of the foam layer

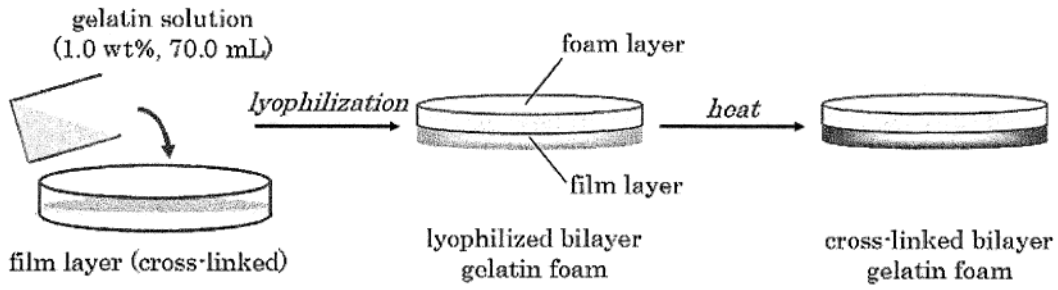


Figure 1. Preparation of gelatin sealing sheet




Figure 2. (a) Photograph of the bilayer gelatin sealing sheet and (b) SEM image of the foam layer

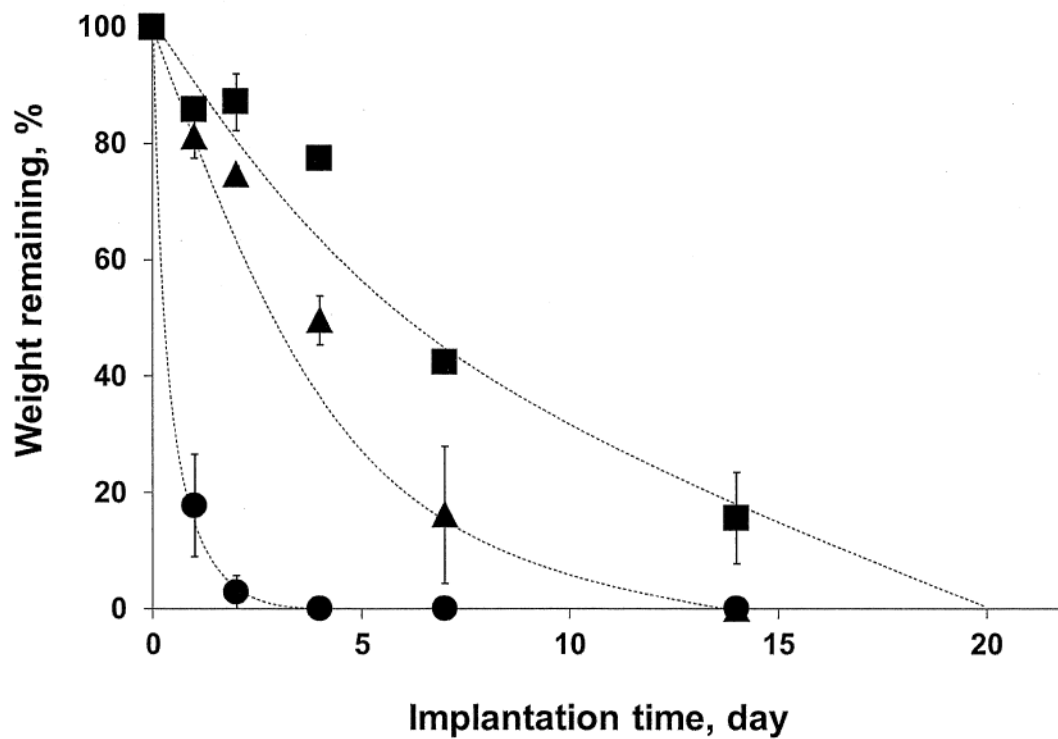


Figure 3. *In vivo* degradation of crosslinked gelatin sealing sheet with different thermal treatment time at 140°C under high vacuum. Treatment time: circle = 2 h, triangle = 3 h, and square = 4 h. Error bars indicate the standard error.

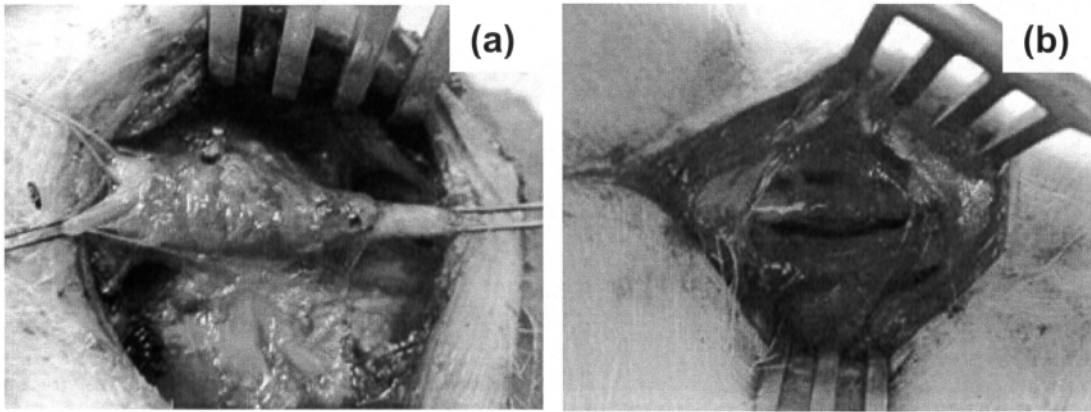


Figure 4. Photographs of femoral arteries 4 weeks after operation: (a) the control group (fibrin glue sealing sheet), and (b) the experimental group (gelatin sealing sheet)

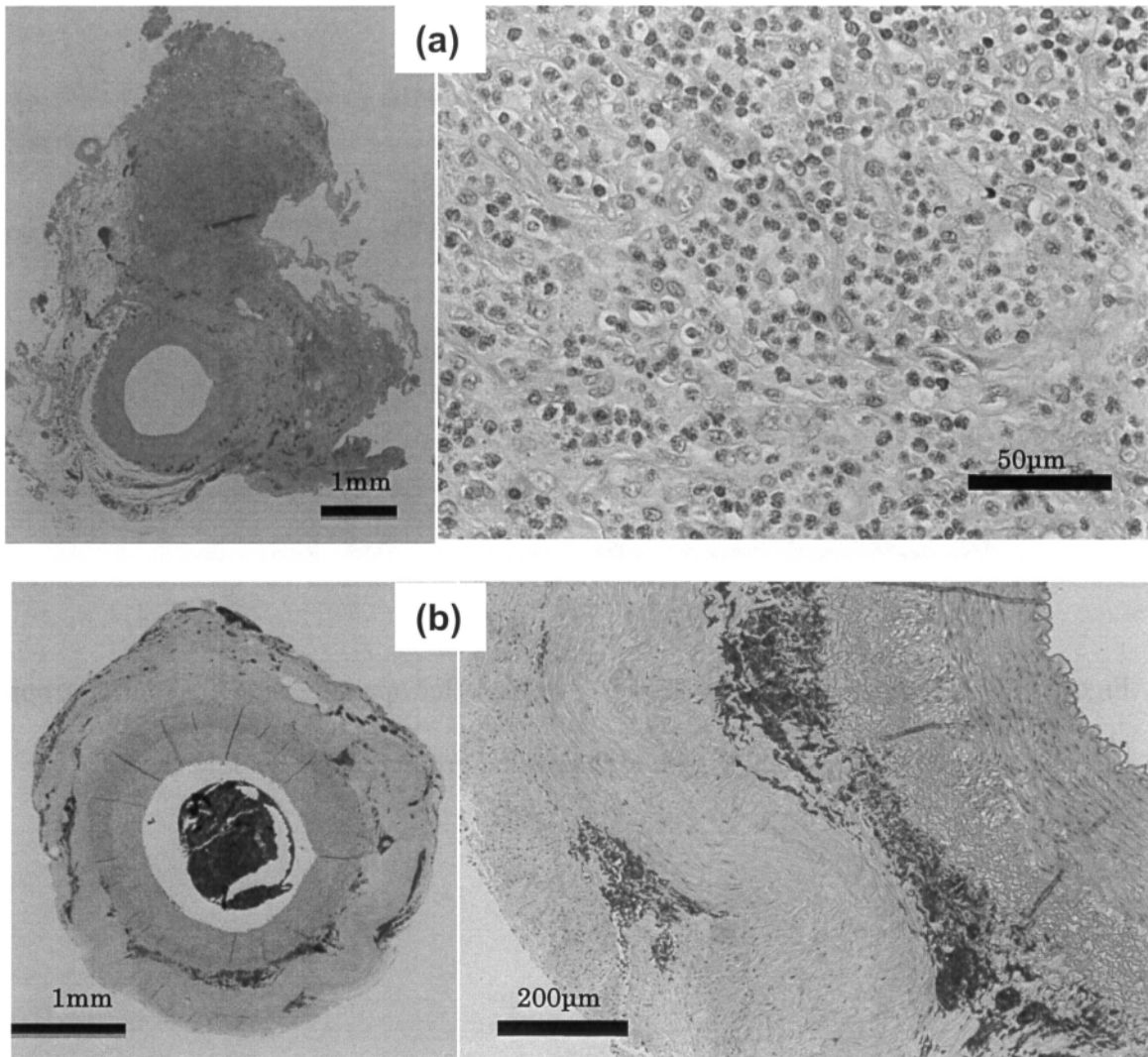


Figure 5. Histological examination of femoral arteries 4 weeks after operation: (a) the control group (fibrin glue sealing sheet), and (b) the experimental group (gelatin sealing sheet)