


# Evaluating Cervical Sagittal Alignment in Cervical Myelopathy: Are Sitting Cervical Radiographs and Standing Whole-Spine Radiographs Equally Useful?

Yasuhiko Morimoto, MD<sup>1,2</sup> , Hideki Shigematsu, MD<sup>1</sup>, Eiichiro Iwata, MD<sup>1</sup>, Masato Tanaka, MD<sup>1</sup>, Akinori Okuda, MD<sup>1</sup>, Keisuke Masuda, MD<sup>1</sup>, Yusuke Yamamoto, MD<sup>1</sup>, Toshichika Takeshima, MD<sup>2</sup>, Yoshiyuki Nakagawa, MD<sup>2</sup>, and Yasuhito Tanaka, MD<sup>1</sup>

Global Spine Journal

1-7

© The Author(s) 2018

Article reuse guidelines:

sagepub.com/journals-permissions

DOI: 10.1177/2192568218811841

journals.sagepub.com/home/gsj



## Abstract

**Study Design:** Retrospective review of medical charts and radiographic data.

**Objectives:** We aimed to clarify the differences in cervical alignment findings between sitting cervical lateral radiographs and standing whole-spine lateral radiographs with clavicle positioning in cervical spondylosis myelopathy (CSM) patients.

**Methods:** We retrospectively evaluated the radiographs of 50 consecutive patients who underwent cervical surgery for CSM in our hospital. Cervical sagittal alignment was evaluated based on the C0-2 angles and C2-7 Gore and Cobb angles. Head position was evaluated in terms of the center of gravity of the head to C7 (CGH-C7) angle and the McGregor angle (ie, the angle between the McGregor line and a horizontal line). The T1-slope was also evaluated.

**Results:** The mean values of the CGH-C7 angle and T1-slope were significantly lower, while the mean value of the McGregor angle was significantly higher on whole-spine lateral radiographs with clavicle positioning than on sitting cervical lateral radiographs. The mean values of the C0-2 and C2-7 angles did not differ significantly between the 2 radiographic positioning approaches.

**Conclusions:** Using whole-spine lateral radiographs with clavicle positioning may result in a significantly lower T1-slope and a posterior tilt of the head. In the absence of a compensatory change in cervical alignment, clavicle positioning may force patients to adopt an upward gazing position of the head. These compensatory mechanisms should be considered while evaluating cervical alignment on whole-spine lateral radiographs with clavicle positioning. Surgical planning should take into account the effect of posture on the radiographic appearance of cervical alignment.

## Keywords

cervical lateral radiograph, whole-spine lateral radiograph, cervical alignment, cervical spondylosis myelopathy, sitting position, occipito-cervical alignment

## Introduction

Cervical spondylosis myelopathy (CSM) may result from spinal cord compression and/or disturbed blood supply due to degenerative changes or instability of the cervical spine.<sup>1</sup> Laminoplasty is a surgical procedure commonly used to treat CSM in Japan. In addition to key factors such as disease pathology, number and location of vertebral levels involved, bone quality, and smoking status, presurgery assessment should carefully consider 2 aspects: (1) cervical alignment, (2) cervical spinal canal diameter, and (3) presence of cervical spine instability such as

spondylolisthesis. Such aspects, especially cervical alignment, may have a critical effect on prognosis. Indeed, several clinical studies reported poor surgical outcomes of laminoplasty due

<sup>1</sup> Nara Medical University, Kashihara City, Nara, Japan

<sup>2</sup> Uda City Hospital, Uda City, Nara, Japan

### Corresponding Author:

Hideki Shigematsu, Department of Orthopedic Surgery, Nara Medical University, 840 Shijo-cho, Kashihara City, Nara 634-8522, Japan.

Email: shideki714@gmail.com



to preoperative malalignment,<sup>2-4</sup> suggesting that cervical alignment is a key factor for good surgical outcomes after cervical laminoplasty. Therefore, it is essential to adequately evaluate cervical alignment prior to cervical spine surgery.

Currently, the conventional imaging approach to evaluate global sagittal spinal alignment before surgery involves the use of whole-spine lateral radiographs, especially in patients with spine disorders such as CSM and in patients with spinal deformities. Whole-spine lateral radiographs are generally taken with clavicle positioning.<sup>5,6</sup> To date, several studies have reported the surgical outcomes of cervical laminoplasty that employed whole-spine lateral radiographs to assess cervical alignment.<sup>7-12</sup> Nevertheless, other studies have suggested that cervical alignment has little effect on the outcomes of surgery for degenerative cervical myelopathy.<sup>13</sup> Thus, it is important to clarify whether posture-associated characteristics (including cervical alignment) may explain the discrepancies among previous observations.

Meanwhile, cervical lateral radiographs, which are also commonly used in the management of cervical spine conditions, are taken with the patient in a relaxed sitting position<sup>14-16</sup> or in standing position<sup>17-20</sup> with the arms on either side of the body, which provides optimal posture to evaluate cervical sagittal alignment. However, there is no consensus regarding the optimal radiographic positioning for lateral views of the cervical spine, and various approaches are used in clinical practice. Evaluation of cervical alignment on sitting radiographs is necessary in some patients with CSM, who cannot stand unaided. To date, the exact correspondence between sitting and standing lateral radiographs in terms of cervical alignment remains unclear. Therefore, we aimed to clarify the differences in cervical alignment findings between sitting cervical lateral radiographs and standing whole-spine lateral radiographs with clavicle positioning in CSM patients.

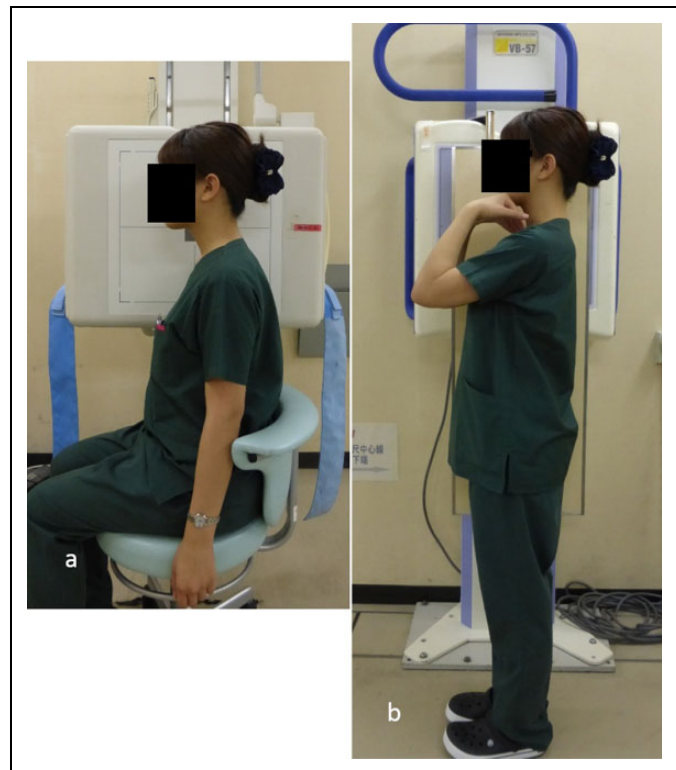## Methods

### Ethics and Patient Consent

This study was approved by the institutional review board of our hospital, and all patients agreed to undergo the procedures and investigations described below. As this was a retrospective study, the requirement for informed consent from the patients to be included in the analysis was waived by the review board.

### Study Participants

We retrospectively reviewed the clinical data of 110 consecutive patients who underwent cervical surgery for CSM between September 2012 and December 2015 at our hospital. We excluded cases involving a history of spinal surgery, trauma, ossification of the posterior longitudinal ligament, atlantoaxial subluxation, difficulty to conduct accurate radiographic measurements due to the shadow of the shoulder, or inability of the patient to stand independently or to achieve adequate clavicle positioning. In total, 50 cases were included in our analysis. All

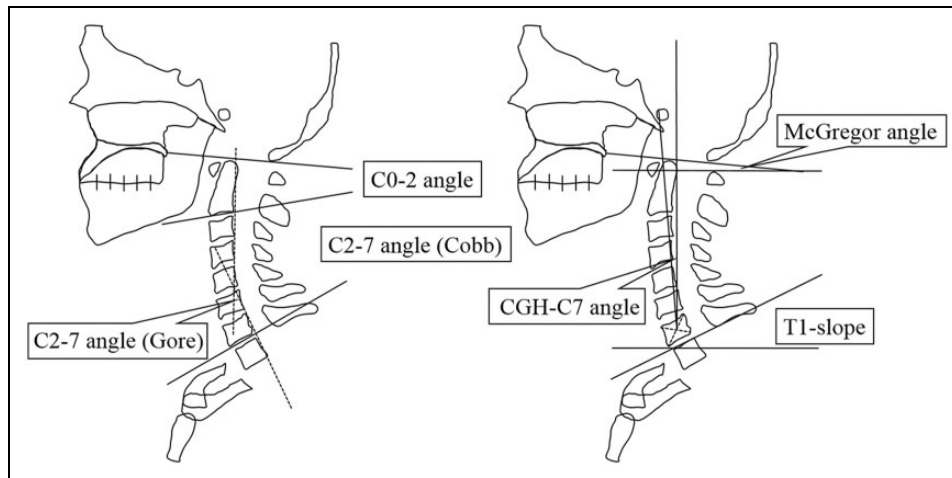


**Figure 1.** Radiographic positioning for evaluating cervical alignment. (a) Patient positioning for sitting cervical lateral radiographs: the patient adopts a relaxed sitting position, with the arms extended and hands on either side. (b) Patient positioning for standing whole-spine lateral radiographs with clavicle positioning: the patient adopts the “clavicle position,” with the elbows flexed and fingers in the supraclavicular fossae. In both positions, the patient is looking straight ahead.

patients were evaluated first on sitting cervical lateral radiographs (with the arms on either side of the body) and then on whole-spine lateral radiographs with clavicle positioning.

### Radiographic Evaluation

In our study, patients were always asked to look straight ahead, and we used a mirror to help the patients maintain their gaze at the same level throughout the measurement. First, the cervical lateral radiograph was taken with the patient sitting and holding the head in a comfortable resting position while maintaining a horizontal gaze, with the arms extended and hands on either side of the body (Figure 1a). Subsequently, the whole-spine lateral radiograph with clavicle positioning was taken with the patient standing and looking straight ahead, holding the elbows and wrists fully flexed and the fingers placed into the ipsilateral supraclavicular fossae, without any external support (Figure 1b).<sup>21</sup> The distance between the X-ray tube and the film was 1.5 m<sup>14,16,22</sup> for the sitting radiograph and 1.8 m<sup>18,23</sup> for the standing radiograph, per the protocol described in other studies. All measurements were made using a digital tool available on the hospital’s image viewing system (SYNAPSE V4.1.3; Fuji Photo Film, Co Ltd, Japan).



**Figure 2.** Measurement of parameters on cervical lateral X-ray scans. Cervical sagittal alignment is evaluated using the C0-2 angle and the C2-7 Cobb and Gore angles. The center of gravity of the head (CGH) is estimated to lie at the anterior margin of the external auditory canal.

The following parameters were measured on each lateral radiograph (Figure 2). Anteroposterior head movement was evaluated in terms of the angle between an imaginary vertical line and a line joining the center of gravity of the head (CGH) and the center of the C7 vertebral body (CGH-C7 angle). Superoinferior tilting of the head was evaluated in terms of the McGregor angle (ie, the angle between the McGregor line and a horizontal line). For all patients, the CGH was considered to lie at the anterior margin of the external auditory canal.<sup>12,17</sup> Cervical sagittal alignment was evaluated using the C0-2 angle and the C2-7 angle. For the C2-7 angle, both the Cobb angle and the Gore angle were measured.<sup>24,25</sup> We employed both methods because, although the Cobb method is often used, some reports have indicated that the standard error of measurement is smaller for the Gore method than for the Cobb method.<sup>26</sup> The cervical sagittal range of motion (ROM) was assessed by measuring the difference in alignment (Cobb C2-7 angle) between the flexion and extension views. Furthermore, the slope between a horizontal line and a line parallel to the superior endplate of T1 (T1-slope) was also evaluated.<sup>27,28</sup> For all measurements, lordosis was considered as positive and kyphosis as negative. All radiographs were independently reviewed by 2 authors who are experienced spine surgeons.

### Statistical Analyses

Statistical analyses were performed using IBM SPSS Statistics, version 24 (SPSS Inc, Chicago, IL). The paired *t* test was used to compare continuous variables. Pearson's correlation coefficient was used to determine the correlation among radiographic parameters. Statistical significance was set at  $P < .05$ . Reliability was graded in terms of the intraclass correlation coefficient (ICC), according to previously described semiquantitative criteria: excellent, 0.9 to 1.0; good, 0.7 to 0.89; fair/moderate, 0.50 to 0.69; low, 0.25 to 0.49; and poor, 0.0 to 0.24.<sup>29</sup>

## Results

### Demographics

The mean age in this patient series was 66.5 years (range = 31-87 years). Of the 50 patients in the series, 26 were male and 24 were female. Among the 50 patients included, 9 had single-level compression, 6 had 2-level compression, 16 had 3-level compression, and 19 had involvement of 4 levels or more. Furthermore, 3 patients had spondylolisthesis, whereas 5 patients had hypertrophy of the ligamentum flavum.

### Occipito-Cervical Parameters

The inter- and intraobserver reliability for all radiographic measurements was graded as good to excellent (ICC > 0.7), with most measurements having excellent reliability (Table 1). The CGH-C7 angle was significantly smaller when measured on standing radiographs with clavicle positioning than when measured on sitting radiographs (mean = 3.8° vs 8.3°;  $P < .001$ ). Conversely, the McGregor angle was larger on standing radiographs with clavicle positioning than on sitting radiographs (mean = 4.7° vs 0.5°;  $P < .001$ ), while the C0-2 angle (mean = 17.4° vs 17.9°;  $P = .533$ ), Cobb C2-7 angle (mean = 7.1° vs 8.2°;  $P = .472$ ), and Gore C2-7 angle (mean = 8.0° vs 10.4°;  $P = .129$ ) did not differ between the 2 radiographic positioning schemes. However, the T1-slope was smaller on standing radiographs with clavicle positioning than on sitting radiographs (mean = 19.4° vs 27.8°;  $P < .001$ ; Table 2). The cervical ROM, which was measured in terms of the Cobb C2-7 angle, was 39.4 ± 13.3° (mean ± standard deviation).

### Correlations Among Radiographic Parameters

The CGH-C7 angle correlated significantly with the McGregor angle (sitting,  $r = -0.437$ ; standing with clavicle positioning,  $r = -0.520$ ) and the T1-slope (sitting,  $r = 0.449$ ; standing with clavicle positioning,  $r = 0.466$ ), but demonstrated no

**Table 1.** Interobserver and Intraobserver Reliability for Parameters Measured on Sitting and Standing Radiographs<sup>a</sup>.

Parameter	Sitting		Standing With Clavicle Positioning	
	Interobserver	Intraobserver	Interobserver	Intraobserver
CGH-C7 angle	0.96	0.96	0.99	0.99
McGregor angle	0.90	0.96	0.83	0.89
C0-2 angle	0.94	0.93	0.97	0.95
C2-7 angle (Cobb)	0.98	0.98	0.77	0.71
C2-7 angle (Gore)	0.97	0.96	0.97	0.94
T1-slope	0.95	0.98	0.96	0.96

Abbreviation: CGH, center of gravity of the head.

<sup>a</sup>Data represents intraclass correlation coefficients.

**Table 2.** Parameters Measured on Sitting and Standing Radiographs<sup>a</sup>.

Parameter	Sitting		Standing With Clavicle Positioning		P
	Mean	95% CI	Mean	95% CI	
CGH-C7	8.3	6.3 to 10.4	3.8	1.7 to 6.0	<.001
McGregor angle	0.3	-2.1 to 2.6	4.7	2.5 to 6.9	<.001
C0-2 angle	17.9	15.0 to 20.8	17.4	14.6 to 20.1	.533
C2-7 angle (Cobb)	8.1	4.2 to 12.0	7.1	3.3 to 10.8	.472
C2-7 angle (Gore)	10.4	6.4 to 14.3	8.4	4.0 to 12.8	.129
T1-slope	27.8	25.3 to 30.3	19.4	15.9 to 22.9	<.001

Abbreviations: CI, confidence interval; CGH, center of gravity of the head.

<sup>a</sup>All measurements are in degrees.

**Table 3.** Correlations Among Parameters Measured on Sitting Radiographs.

Parameter	CGH-C7 Angle	McGregor Angle	C0-2 Angle	C2-7 Angle (Cobb)	C2-7 Angle (Gore)	T1-Slope
CGH-C7 angle		-0.437*	0.243	-0.120	-0.16	0.449*
McGregor angle			0.422*	0.203	0.19	-0.180
C0-2 angle				-0.365*	-0.358**	0.129
C2-7 angle (Cobb)					0.927*	0.539*
C2-7 angle (Gore)						0.604*
T1-slope						

Abbreviation: CGH, center of gravity of the head.

\* $P < .01$ . \*\* $P < .05$ .

significant correlation with the C2-7 angle. On the other hand, the C2-7 angle correlated significantly with the T1-slope (sitting,  $r = 0.539$  for Cobb and  $r = 0.604$  for Gore angles; standing with clavicle positioning,  $r = 0.400$  for Cobb and  $r = 0.353$  for Gore angles; Tables 3 and 4).

## Discussion

To date, cervical sagittal alignment has generally been evaluated on either sitting<sup>14-16</sup> or standing radiographs.<sup>17-20</sup> Although careful assessment of preoperative cervical alignment is very important in cervical spine surgery, it remains unclear whether the findings of cervical sagittal alignment for these 2 radiographic positioning schemes are equivalent. In our study, we found that using clavicle positioning for whole-spine radiographs resulted in a substantially decreased T1-slope and

CGH-C7 angle compared with the values obtained for sitting radiographs, suggesting that the head is more posteriorly tilted when using clavicle positioning. Furthermore, the McGregor angle was greater when using clavicle positioning.

Our present results indicate that radiographic positioning affects the head position but not the C0-2 angle or the C2-7 angle. This difference in cervical alignment findings between sitting and standing radiographs should be kept in mind during surgical planning. While such a conclusion might be expected, it should be noted that not all clinical papers mention the posture used for cervical spine radiographs.<sup>30,31</sup>

Previous studies reported that a greater T1-slope yielded a greater magnitude of cervical lordosis,<sup>18,32</sup> which is in agreement with our present results in that the C2-7 angle (Cobb and Gore) correlated significantly with the T1-slope (sitting,  $r = 0.539$  and  $r = 0.604$ , respectively; standing with clavicle

**Table 4.** Correlations Among Parameters Measured on Standing Radiographs With Clavicle Positioning.

Parameter	CGH-C7 Angle	McGregor Angle	C0-2 Angle	C2-7 Angle (Cobb)	C2-7 Angle (Gore)	T1-Slope
CGH-C7 angle		-0.520*	0.364*	-0.238	-0.267	0.466*
McGregor angle			0.345**	0.412*	0.414*	-0.070
C0-2 angle				-0.268	-0.251	0.179
C2-7 angle (Cobb)					0.970*	0.400*
C2-7 angle (Gore)						0.353**
T1-slope						

Abbreviation: CGH, center of gravity of the head.

\* $P < .01$ . \*\* $P < .05$ .

**Table 5.** Comparison of Cervical ROM Findings on Cervical Lateral Radiographs.

Study	Population	Number of Cases	Mean Age (Years)	C2-7 Angle ROM ( $^{\circ}$ )	
				Mean	SD
Machino et al <sup>19</sup>	CSM	1016	62.2	39.4	10.9
	Asymptomatic	1230		55.3	16.0
Present study	CSM	50	66.5	39.4	13.3

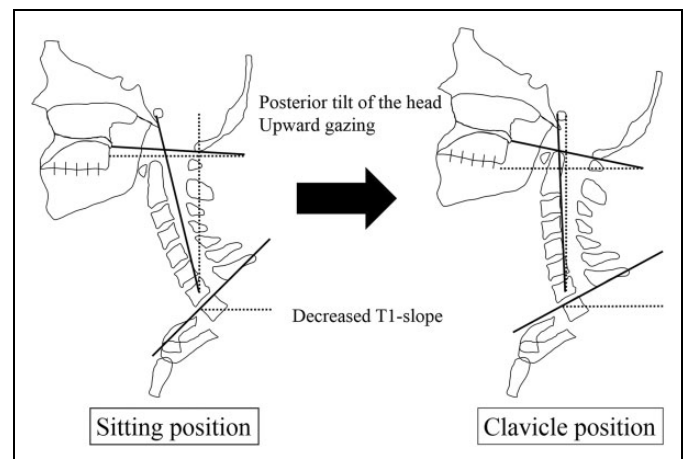
Abbreviations: CSM, cervical spondylotic myelopathy; ROM, range of motion; SD, standard deviation.

positioning,  $r = 0.400$  and  $r = 0.353$ , respectively). However, we found that the T1-slope was lower when using clavicle positioning (sitting,  $27.8^{\circ}$ ; standing with clavicle positioning,  $19.4^{\circ}$ ;  $P < .001$ ).

Park et al<sup>18</sup> analyzed the differences in cervical sagittal alignment between standing cervical lateral radiographs and whole-spine lateral radiographs in healthy adults, reporting that the use of clavicle positioning for whole-spine radiographs was associated with a substantially lower T1-slope and more posterior position of the head, which translated into a less lordotic cervical sagittal alignment (relative to findings on regular standing cervical radiographs). These previous findings are in agreement with our present results in that clavicle positioning was associated with a substantially lower T1-slope and a posterior tilt of the head. However, we found no difference between the 2 radiographic positioning schemes regarding cervical sagittal alignment (C0-2 and C2-7 angles).

Machino et al<sup>19</sup> reported that, compared with asymptomatic individuals, symptomatic patients with CSM have significantly smaller lordotic angles and reduced ROM. In their study, C2-7 ROM was  $39.4^{\circ}$  in CSM patients and  $55.3^{\circ}$  in asymptomatic subjects. We obtained similar findings in this series of CSM patients (C2-7 ROM,  $39.4^{\circ}$ ; Table 5). Since our study included only patients with CSM, the similarity of cervical sagittal alignment angles (C0-2 and C2-7) between the 2 radiographic positioning schemes (sitting vs standing with clavicle positioning) may be explained by the limited ROM associated with CSM.

We found that the McGregor angle was higher when using clavicle positioning (sitting,  $0.3^{\circ}$ ; standing with clavicle positioning,  $4.7^{\circ}$ ;  $P < .001$ ), which suggests that clavicle positioning may force patients to adopt an upward gazing position of the head. In our study, patients were always asked to look straight ahead and we used a mirror to help them maintain their gaze in



**Figure 3.** Comparison of sagittal occipito-cervical parameters measured on sitting radiographs and on standing radiographs with clavicle positioning. Clavicle positioning results in a posterior tilt of the head, decreased T1-slope, and upward gaze.

the appropriate direction throughout the measurement. However, our data indicates that the head position was upward gazing for whole-spine radiographs (relative to the head position for sitting radiographs), which is reflected in 2 key findings regarding clavicle positioning, namely, the substantially lower T1-slope and posterior tilt of the head without changes in cervical sagittal alignment angles. Since cervical alignment did not compensate for the head tilt, maintaining clavicle positioning may have forced the patients to adopt an upward gaze, which was confirmed by the increased McGregor angle (Figure 3).

Whole-spine lateral radiographs can be taken with the patient holding the arms in various positions,<sup>33,34</sup> but clavicle positioning is considered superior as it offers better

visualization of the thoracic spine, which in turn allows for better assessment of global spinal alignment.<sup>21,35</sup> Several studies have reported on the changes in cervical spine alignment secondary to postural variations during radiography.<sup>18,23</sup> To the best of our knowledge, the present study was the first to evaluate the differences in cervical alignment between sitting cervical lateral radiographs and whole-spine lateral radiographs.

The CGH-C7 SVA (sagittal vertical axis) is frequently used to evaluate the position of the head relative to the cervical spine.<sup>12,17</sup> However, in different hospitals, cervical radiographs are taken using setups that involve different distances between the X-ray tube and film,<sup>14,18-20,22,23,27</sup> which diminishes reproducibility because the CGH-C7 SVA is affected by magnification error.<sup>22</sup> Instead, we used the CGH-C7 angle, defined as the angle between an imaginary vertical line and the line joining the CGH and the center of the C7 vertebral body. The CGH-C7 angle is a more objective parameter because it does not vary with the distance between the patient and the X-ray tube.

The current study has several limitations. First, we only included patients with CSM; we did not include healthy subjects in order to avoid unnecessary exposure to ionizing radiation. Prospective studies with large samples of CSM patients and healthy individuals are warranted to clarify the effect of CSM on cervical alignment. Second, we only evaluated radiographic parameters measured with the patient sitting while holding the arms extended on either side of the body, as well as those obtained with the patient standing while holding the arms and wrists flexed, with the fingers placed into the ipsilateral supraclavicular fossae. Future studies should clarify the effect of arm positioning on cervical alignment. Third, the sample size was relatively small. Fourth, because the sample size was small, we could not conduct subgroup analysis based on disease pathology. Fifth, we did not evaluate the alignment further than T1, which did not allow us to consider a possible compensatory change derived from the thoracolumbar region.

## Conclusion

Despite its limitations, our study demonstrated that clavicle positioning may result in a significantly lower T1-slope and a posterior tilt of the head, which, in the absence of a compensatory change in cervical sagittal alignment, may force patients to adopt an upward gazing position of the head. Thus, when evaluating cervical alignment before surgery, we should keep in mind the effect of posture on the radiographic appearance of cervical alignment.


## Declaration of Conflicting Interests

The author(s) declared no potential conflicts of interest with respect to the research, authorship, and/or publication of this article.

## Funding

The author(s) received no financial support for the research, authorship, and/or publication of this article.

## ORCID iD

Yasuhiko Morimoto  <https://orcid.org/0000-0002-1736-8800>

## Ethical Approval and Patient Consent

This study was approved by the institutional review board of Nara Medical University (Approval Number: 1636), and all patients agreed to undergo the procedures and investigations described in the article. As this was a retrospective study, the requirement for informed consent from the patients to be included in the analysis was waived by the review board. The staff member pictured in Figure 1 provided written consent for publication of the figure as part of this article.

## References

- Toledano M, Bartleson JD. Cervical spondylotic myelopathy. *Neurol Clin*. 2013;31:287-305.
- Suda K, Abumi K, Ito M, Shono Y, Kaneda K, Fujiya M. Local kyphosis reduces surgical outcomes of expansive open-door laminoplasty for cervical spondylotic myelopathy. *Spine (Phila Pa 1976)*. 2003;28:1258-1262.
- Sodeyama T, Goto S, Mochizuki M, Takahashi J, Moriya H. Effect of decompression enlargement laminoplasty for posterior shifting of the spinal cord. *Spine (Phila Pa 1976)*. 1999;24:1527-1532.
- Kim TH, Lee SY, Kim YC, Park MS, Kim SW. T1 slope as a predictor of kyphotic alignment change after laminoplasty in patients with cervical myelopathy. *Spine (Phila Pa 1976)*. 2013;38:E992-E997.
- Schwab F, Ungar B, Blondel B, et al. Scoliosis Research Society—Schwab adult spinal deformity classification: a validation study. *Spine (Phila Pa 1976)*. 2012;37:1077-1082.
- Abelin-Genevois K, Idjerouidene A, Roussouly P, Vital JM, Garin C. Cervical spine alignment in the pediatric population: a radiographic normative study of 150 asymptomatic patients. *Eur Spine J*. 2014;23:1442-1448.
- Cho JH, Hwang CJ, Choi YH, Lee DH, Lee CS. Cervical sagittal alignment in patients with adolescent idiopathic scoliosis: is it corrected by surgery? *J Neurosurg Pediatr*. 2018;21:292-301.
- Wang F, Zhou XY, Xu XM, et al. Cervical sagittal alignment limited adjustment after selective posterior thoracolumbar/lumbar curve correction in patients with Lenke type 5C adolescent idiopathic scoliosis. *Spine (Phila Pa 1976)*. 2017;42:E539-E546.
- Ames CP, Blondel B, Scheer JK, et al. Cervical radiographical alignment: comprehensive assessment techniques and potential importance in cervical myelopathy. *Spine (Phila Pa 1976)*. 2013;38:S149-S160.
- Kato M, Namikawa T, Matsumura A, Konishi S, Nakamura H. Effect of cervical sagittal balance on laminoplasty in patients with cervical myelopathy. *Global Spine J*. 2017;7:154-161.
- Oshima Y, Takeshita K, Taniguchi Y, et al. Effect of preoperative sagittal balance on cervical laminoplasty outcomes. *Spine (Phila Pa 1976)*. 2016;41:E1265-E1270.
- Sakai K, Yoshii T, Hirai T, et al. Cervical sagittal imbalance is a predictor of kyphotic deformity after laminoplasty in cervical spondylotic myelopathy patients without preoperative kyphotic alignment. *Spine (Phila Pa 1976)*. 2016;41:299-305.

13. Kato S, Nouri A, Wu D, Nori S, Tetreault L, Fehlings MG. Impact of cervical spine deformity on preoperative disease severity and postoperative outcomes following fusion surgery for degenerative cervical myelopathy: sub-analysis of AOSpine North America and International studies. *Spine (Phila Pa 1976)*. 2018;43:248-254.
14. Nojiri K, Matsumoto M, Chiba K, et al. Relationship between alignment of upper and lower cervical spine in asymptomatic individuals. *J Neurosurg*. 2003;99:80-83.
15. Matsubayashi Y, Shimizu T, Chikuda H, Takeshita K, Oshima Y, Tanaka S. Correlations of cervical sagittal alignment before and after occipitocervical fusion. *Global Spine J*. 2016;6:362-369.
16. Okada E, Matsumoto M, Ichihara D, et al. Does the sagittal alignment of the cervical spine have an impact on disk degeneration? Minimum 10-year follow-up of asymptomatic volunteers. *Eur Spine J*. 2009;18:1644-1651.
17. Tang JA, Scheer JK, Smith JS, et al. The impact of standing regional cervical sagittal alignment on outcomes in posterior cervical fusion surgery. *Neurosurgery*. 2012;71:662-669.
18. Park SM, Song KS, Park SH, Kang H, Riew KD. Does whole-spine lateral radiograph with clavicle positioning reflect the correct cervical sagittal alignment? *Eur Spine J*. 2015;24:57-62.
19. Machino M, Yukawa Y, Imagama S, et al. Age-related and degenerative changes in the osseous anatomy, alignment, and range of motion of the cervical spine: a comparative study of radiographic data from 1016 patients with cervical spondylotic myelopathy and 1230 asymptomatic subjects. *Spine (Phila Pa 1976)*. 2016;41:476-482.
20. Yukawa Y, Kato F, Suda K, Yamagata M, Ueta T. Age-related changes in osseous anatomy, alignment, and range of motion of the cervical spine. Part I: radiographic data from over 1200 asymptomatic subjects. *Eur Spine J*. 2012;21:1492-1498.
21. Horton WC, Brown CW, Bridwell KH, Glassman SD, Suk SI, Cha CW. Is there an optimal patient stance for obtaining a lateral 36" radiograph? A critical comparison of three techniques. *Spine (Phila Pa 1976)*. 2005;30:427-433.
22. Shigematsu H, Koizumi M, Yoneda M, Iida J, Oshima T, Tanaka Y. Magnification error in digital radiographs of the cervical spine against magnetic resonance imaging measurements. *Asian Spine J*. 2013;7:267-272.
23. Park MS, Moon SH, Kim TH, Oh JK, Kang HJ, Riew KD. Radiographic comparison between cervical spine lateral and whole-spine lateral standing radiographs. *Global Spine J*. 2016;6:118-123.
24. Scheer JK, Tang JA, Smith JS, et al; International Spine Study Group. Cervical spine alignment, sagittal deformity, and clinical implications: a review. *J Neurosurg Spine*. 2013;19:141-159.
25. Gore DR, Sepic SB, Gardner GM. Roentgenographic findings of the cervical spine in asymptomatic people. *Spine (Phila Pa 1976)*. 1986;11:521-524.
26. Harrison DE, Harrison DD, Cailliet R, Troyanovich SJ, Janik TJ, Holland B. Cobb method or Harrison posterior tangent method: which to choose for lateral cervical radiographic analysis. *Spine (Phila Pa 1976)*. 2000;25:2072-2078.
27. Armijo-Olivo S, Jara X, Castillo N, et al. A comparison of the head and cervical posture between the self-balanced position and the Frankfurt method. *J Oral Rehabil*. 2006;33:194-201.
28. Rocabado M. Biomechanical relationship of the cranial, cervical, and hyoid regions. *J Craniomandibular Pract*. 1983;1:61-66.
29. Landis JR, Koch GG. An application of hierarchical kappa-type statistics in the assessment of majority agreement among multiple observers. *Biometrics*. 1977;33:363-374.
30. Fujiyoshi T, Yamazaki M, Kawabe J, et al. A new concept for making decisions regarding the surgical approach for cervical ossification of the posterior longitudinal ligament: the K-line. *Spine (Phila Pa 1976)*. 2008;33:E990-E993.
31. Gu Y, Shi J, Cao P, et al. Clinical and imaging predictors of surgical outcome in multilevel cervical ossification of posterior longitudinal ligament: an analysis of 184 patients. *PLoS One*. 2015;10:e0136042.
32. Lee SH, Kim KT, Seo EM, Suk KS, Kwack YH, Son ES. The influence of thoracic inlet alignment on the craniocervical sagittal balance in asymptomatic adults. *J Spinal Disord Tech*. 2012;25:E41-E47.
33. Aota Y, Saito T, Uesugi M, Ishida K, Shinoda K, Mizuma K. Does the fists-on-clavicles position represent a functional standing position? *Spine (Phila Pa 1976)*. 2009;34:808-812.
34. Vedantam R, Lenke LG, Bridwell KH, Linville DL, Blanke K. The effect of variation in arm position on sagittal spinal alignment. *Spine (Phila Pa 1976)*. 2000;25:2204-2209.
35. Faro FD, Marks MC, Pawelek J, Newton PO. Evaluation of a functional position for lateral radiograph acquisition in adolescent idiopathic scoliosis. *Spine (Phila Pa 1976)*. 2004;29:2284-2249.