

1  
2  
3  
4  
5  
6  
7  
8  
9  
10  
11  
12  
13  
14  
15  
16  
17  
18  
19  
20  
21  
22  
23  
24  
25  
26  
27  
28  
29  
30  
31  
32  
33  
34  
35  
36  
37  
38  
39  
40  
41  
42  
43  
44  
45  
46  
47  
48  
49  
50  
51  
52  
53  
54  
55  
56  
57  
58  
59  
60  
61  
62  
63  
64  
65

**Title**

Plaque Modification of Severely Calcified Coronary Lesions by Scoring Balloon Angioplasty Using

Lacrosse Non-slip Element: Insights from an Optical Coherence Tomography Evaluation

Short title: Scoring balloon angioplasty for calcified lesions

Yu Sugawara, MD, Tomoya Ueda, MD, Tsunenari Soeda, MD, Makoto Watanabe, MD, Hiroyuki Okura,

MD, Yoshihiko Saito, MD

Department of Cardiology, Nara Medical University, Japan

Corresponding author:

Yu Sugawara, MD

Department of Cardiology, Nara Medical University

840 Shijo-cho, Kashihara, Nara, Japan 634-8522

Phone +81-744-22-3051 Ex. 3411, Fax +81-744-22-9726

E-mail: [waegurorunsra@hotmail.co.jp](mailto:waegurorunsra@hotmail.co.jp)

Thank you for your valuable and important comments for improving our manuscript.

I believe that incorporating your suggestions into the revised version has enhanced the quality of our manuscript. We hope that you will now find it acceptable for publication.

Sincerely,

Yu Sugawara, MD

Nara Medical University

## Abstract

Percutaneous coronary intervention (PCI) for heavily calcified lesions is challenging because these lesions are resistant to balloon dilatation and stenting. **Lacrosse non-slip element (NSE)** may have the potential to dilate heavily calcified lesions. We aimed to investigate predictors of successful lesion modification using **Lacrosse NSE** angioplasty via optical coherence tomography (OCT)-guided PCI.

We investigated 32 patients with severe target lesion calcification treated with OCT-guided PCI. Successful lesion modification was defined as the complete **fracture** of calcification after **Lacrosse NSE** angioplasty.

Before PCI, 172 segments with calcification were identified. After pre-dilatation using Lacrosse NSE, successful lesion modification was achieved in 117 segments (68.0%). **Calcification was significantly thinner in successfully disrupted segments than in non-disrupted segments ( $p < 0.001$ ). Calcification angle tended to be larger in disrupted than in non-disrupted segments ( $p = 0.08$ ). Convex types were less frequently observed in disrupted than in non-disrupted segments ( $p < 0.001$ ). At minimal lumen area sites, 26 segments (81.3%) were successfully modified. Similar to the overall results, the disrupted group had significantly thinner calcification than the non-disrupted group ( $p < 0.001$ ). The angle of the calcified plaque was similar between the 2 groups ( $p = 0.39$ ). Convex-type calcifications were less frequently observed in the disrupted group than in the non-disrupted group ( $p = 0.05$ ). Receiver-operating characteristic curve analysis showed that calcification thickness  $<565 \mu\text{m}$  was the best predictor of**

1  
2  
3 **completely disrupted calcification.**  
4

5  
6 The thickness and shape of calcifications were predictors of successful lesion modification after  
7

8  
9  
10 **Lacrosse NSE** angioplasty.  
11

12  
13 **Key words:** percutaneous coronary intervention, scoring balloon angioplasty, coronary calcified lesion,  
14

15  
16 optical coherence tomography  
17  
18  
19  
20  
21  
22  
23  
24  
25  
26  
27  
28  
29  
30  
31  
32  
33  
34  
35  
36  
37  
38  
39  
40  
41  
42  
43  
44  
45  
46  
47  
48  
49  
50  
51  
52  
53  
54  
55  
56  
57  
58  
59  
60  
61  
62  
63  
64  
65

## Introduction

Heavily calcified coronary lesions are one of the most challenging subsets of lesions to manage during percutaneous coronary intervention (PCI) because they interfere with the ability of the balloon or stent to cross and may exhibit strong resistance to balloon dilatation. Even with the use of second- or third-generation drug-eluting stents (DES), stent under-expansion has been consistently reported as a strong predictor for stent restenosis as well as stent thrombosis [1, 2]. Therefore, to expand the coronary stent appropriately, effective lesion modification, prior to stent implantation, is required.

“Scoring balloons” have 2 or 3 scoring elements that prevent balloon slippage and create a crack in the calcified plaque [3, 4]. Although pre-dilatation via the Lacrosse non-slip element (NSE; Goodman. Co., Ltd., Nagoya, Japan) scoring balloon may be effective for modifying heavily calcified lesions [5], the rates and predictors of effective lesion modification are still uncertain.

Optical coherence tomography (OCT) is a near-infrared light-based intracoronary imaging modality that provides high-resolution images of the vascular wall and can detect different characteristics of atherosclerotic plaques [6–9]. OCT provides more accurate morphological and quantitative information of the calcified plaque than intravascular ultrasound [8, 10].

Accordingly, this study was conducted to determine if OCT imaging could identify the predictors of successful modification of heavily calcified lesions after pre-dilatation using a Lacrosse NSE balloon.

## Methods

## Study population

Between January 2013 and December 2014, 32 consecutive patients who underwent OCT-guided PCI for heavily calcified coronary lesions were enrolled. Heavily calcified coronary lesions were defined based on fluoroscopic appearance as lesions with readily apparent radio-opacities within the vascular walls in more than 1 projection on cine images before contrast medium injection.

The inclusion criteria were as follows: (1) symptomatic angina pectoris with significant coronary stenosis (>75% diameter), and (2) severely calcified lesions treated using a scoring balloon followed by second- or third-generation DES implantation.

The following cases were excluded: (1) restenotic lesions, (2) totally occluded lesions, (3) cases where pre- and/or post-angiography OCT images could not be obtained because the OCT catheter could not cross the target lesions, (4) cases with poor or incomplete OCT image quality because of vessel tortuosity or incomplete removal of blood during OCT imaging, and (5) lesions treated with rotational atherectomy.

Successful lesion modification was defined as the creation of 1 or more complete **fracture** of the calcification after pre-dilatation.

After PCI, we performed a 3-year follow-up investigation and examined the number of target lesion revascularizations (TLRs). TLR was defined as PCI or bypass surgery because of restenosis or thrombotic events at the target lesion, which includes the proximal and distal edge segments.

## PCI and OCT procedures

1  
2  
3 Coronary angiography and PCI were performed using the standard technique via a radial or femoral  
4  
5  
6 approach using a 6- or 7-Fr guiding catheter. After diagnostic coronary angiography, a commercially  
7  
8  
9 available frequency-domain OCT catheter (C7/C8 OCT imaging system; St. Jude Medical, MN, USA or  
10  
11  
12 OFDI system; Terumo Corporation, Tokyo, Japan) was inserted to obtain cross-sectional images of the  
13  
14  
15 target lesion prior to any interventional procedures. After intracoronary nitrate injection to achieve  
16  
17  
18 maximal vasodilatation, OCT images were acquired using an automated pullback (20 mm/s). Because  
19  
20  
21 calcified plaques may be present throughout the target lesion, we measured and analyzed multiple  
22  
23  
24 cross-sectional images of the calcified plaque, including the minimal lumen area (MLA) sites at 1-mm  
25  
26  
27 intervals. In addition, a similar analysis was also performed using cross-sectional images from the MLA  
28  
29  
30 site only. After OCT imaging, pre-dilatation of the target lesion was performed using a scoring balloon  
31  
32  
33 (Lacrosse NSE ALPHA; Goodman, Nagoya, Japan). The size of the balloon was selected at each  
34  
35  
36 operator's discretion based on the angiography and OCT findings. After pre-dilatation, OCT imaging was  
37  
38  
39 repeated to assess lesion modification and the DES was implanted with subsequent high-pressure  
40  
41  
42 post-dilatation.  
43  
44  
45

#### 46 47 **Analysis of OCT imaging**

48  
49  
50 Calcified plaques were defined as well-delineated, signal-poor regions with sharp borders. We mainly  
51  
52  
53 examined the calcified plaque around the MLA. The longitudinal length, thickness of the calcified plaque,  
54  
55  
56 calcification angle, and shape of calcification were examined at every 1-mm increment. We classified the  
57  
58  
59  
60  
61  
62  
63  
64  
65

1  
2  
3 shape of the calcification as either convex type or non-convex type. Convex-type calcifications were  
4  
5  
6 defined as those that curve outward from the vessel lumen. Otherwise, the other calcifications were  
7  
8  
9 defined as non-convex type.  
10

11  
12 After pre-dilatation using scoring balloon, disruption of the calcified plaque was determined via OCT.

13  
14 OCT showed circumferential calcification before (Figure 1a) and after (Figure 1b) PCI. Figure 1b shows  
15  
16 3 calcium fractures. The thickness of the calcification in each fracture was 520, 470, and 440  $\mu\text{m}$ ,  
17  
18  
19 respectively. In this case, the coronary calcification angle was  $360^\circ$  and the shape was non-convex.  
20  
21  
22

23  
24 Segments with disrupted calcified plaque were compared to those without disruption to investigate  
25  
26  
27  
28  
29 predictors of calcification disruption.  
30

### 31 **Angiographic follow-up**

32  
33 Angiographic follow-ups were scheduled at 9 months following the index procedure. TLR was defined  
34  
35  
36 as ischemia-driven repeated revascularization of the target lesions including stented segments and stent  
37  
38  
39 edges (within 5 mm from both proximal and distal stent edges).  
40  
41  
42

### 43 **Statistical analysis**

44  
45 All analyses were performed using SPSS version 19 (SPSS Inc., Chicago, IL, USA). Continuous  
46  
47  
48 variables are presented as mean  $\pm$  standard deviation, and categorical variables as frequencies and  
49  
50  
51 percentages. Continuous variables were compared using an unpaired Student's t-test or Wilcoxon  
52  
53  
54 rank-sum test based on their distribution. Categorical data were evaluated using the chi-square test or  
55  
56  
57  
58  
59  
60  
61  
62  
63  
64  
65



1  
2  
3 Fisher's exact test, as appropriate. A receiver-operating characteristic curve (ROC) was used to determine  
4  
5  
6 the best cutoff values for predicting the optimal coronary calcification thickness for disruption by scoring  
7  
8  
9 balloon angioplasty. The best cutoff values were defined as those with the highest sum of Youden's index  
10  
11  
12 (sensitivity + specificity - 1). A p-value of <0.05 was considered to indicate statistical significance.  
13  
14

## 15 **Results**

16  
17 A total of 172 cross-sections with calcification were selected from 32 lesions.  
18  
19

20  
21  
22 Table 1 shows the patient population and baseline characteristics. The angiography and procedure  
23  
24 characteristics are presented in Table 2. Most PCIs were performed on the left anterior descending arteries.  
25  
26

27  
28 The mean longitudinal length of the calcified plaque was  $17.1 \pm 12.9$  mm. The MLA and the minimum  
29  
30 and maximum diameter at the culprit site after PCI were significantly larger than before PCI. The mean  
31  
32 scoring balloon diameter was  $2.61 \pm 0.30$  mm, and the mean balloon pressure before lesion modification  
33  
34 was  $11.9 \pm 3.2$  atm. We deployed the stents in all except for 1 patient. The mean stent diameter was  $2.81$   
35  
36  $\pm 0.28$  mm, mean total stent length was  $36.7 \pm 18.4$  mm, mean number of stents was  $1.4 \pm 0.61$ , and  
37  
38 post-dilatation pressure was  $17.2 \pm 4.5$  atm. **Coronary perforation was not observed.** Everolimus-eluting  
39  
40 stents were mainly used. Table 3 shows a comparison of the disrupted and non-disrupted sites. Before PCI,  
41  
42 172 cross-sectional segments with calcified plaque were identified by OCT. After pre-dilatation using the  
43  
44 scoring balloon, successful lesion modification (= complete disruption of the calcified plaque) was  
45  
46 achieved in 117 segments (68%, disrupted group). The remaining 55 segments (32%) were not  
47  
48  
49  
50  
51  
52  
53  
54  
55  
56  
57  
58  
59  
60  
61  
62  
63  
64  
65

1  
2  
3 successfully modified (non-disrupted group). In the disrupted group, the calcified plaque was  
4  
5  
6 significantly thinner than in the non-disrupted group ( $0.35 \pm 0.14$  mm vs.  $0.79 \pm 0.13$  mm,  $p < 0.001$ ).  
7  
8  
9 Conversely, the angle of the calcified plaque tended to be larger in the segments with calcification  
10  
11  
12 disruption than in those with disruption ( $256.2^\circ \pm 84.4$  vs.  $232.7^\circ \pm 73.9$ ,  $p = 0.08$ ). However, there was  
13  
14  
15 no statistical significance between the groups. The convex type of angle was less frequently observed in  
16  
17  
18 the disrupted group than in the non-disrupted group (4.3% vs. 21.8%,  $p < 0.001$ ). Table 4 shows the  
19  
20  
21 results of OCT analyses for the MLA sites. Successful lesion modification was achieved in 26 segments  
22  
23  
24 (81.3%, disrupted group) but not in 6 segments (non-disrupted group). Similar to the overall results, the  
25  
26  
27 disrupted group had significantly thinner calcification than the non-disrupted group ( $0.38 \pm 0.17$  mm vs.  
28  
29  
30  $0.79 \pm 0.19$  mm,  $p < 0.001$ ). There were no significant differences in the longitudinal length of  
31  
32  
33 calcification between the 2 groups. The angle of the calcified plaque was similar between the 2 groups  
34  
35  
36 ( $274.6 \pm 74.0^\circ$  vs.  $243.3 \pm 99.9^\circ$ ,  $p = 0.39$ ). The convex type of calcification was less frequently observed  
37  
38  
39 in the disrupted group than in the non-disrupted group (3.85% vs. 33.3%,  $p = 0.05$ ). Stent delivery was  
40  
41  
42 successfully completed in all patients (100%) in the disrupted group and in 5 patients (83%) in the  
43  
44  
45 non-disrupted group. Incomplete stent apposition was present in 19 patients (73%) in the disrupted group  
46  
47  
48 and in 6 patients (100%) in the non-disrupted group.  
49  
50  
51

52  
53 The ROC curve analysis showed that a calcification thickness of  $<565$   $\mu\text{m}$  (area under the curve [AUC]  
54  
55  
56 0.928, sensitivity 85.3%, specificity 91.4%) was the best cutoff value for predicting calcification  
57  
58  
59  
60  
61  
62  
63  
64  
65

1  
2  
3 disruption (Figure 2). In a subset of 101 segments with a calcification angle of  $>270^\circ$ , the ROC curve  
4  
5  
6 showed that a calcification thickness of  $<535 \mu\text{m}$  (AUC 0.930; 95% confidence interval 0.873–0.987,  
7  
8  
9 sensitivity 86.7%, specificity 85.9%) was the best cutoff value for predicting calcification disruption  
10  
11  
12 (Figure 3).  
13

14  
15 Angiographic follow-up was performed in 29 of 32 patients (90.6%). During follow-up (median 295  
16  
17 days), TLR was documented in 3 of 29 patients (10.3%) (2 [7.7%] in the disrupted group and 1 [16.7%]  
18  
19 in the non-disrupted group).  
20  
21  
22  
23

## 24 25 Discussion

26  
27  
28 The principal findings of this study were that lesion modification could be achieved in 68% of the  
29  
30 heavily calcified coronary arterial segments after pre-dilatation using a scoring balloon, and that the  
31  
32 thickness and morphology of the calcified plaque were successful predictors of lesion modification.  
33  
34  
35

36  
37  
38 Coronary artery stenosis with heavily calcified lesions can be challenging for coronary interventionists  
39  
40 because of the strong resistance to balloon dilatation or stent implantation [11–13]. A previous OCT study  
41  
42 demonstrated that the amount (area) and distribution (angle) of the calcified plaque may be associated  
43  
44 with stent expansion [10]. In addition, incomplete stent apposition may also occur after stent deployment  
45  
46 to calcified lesions with irregular surfaces and convex shapes [14]. Stent under-expansion, a small MLA,  
47  
48 and the length of the stent are often reported as major factors for stent restenosis and thrombosis [15–18].  
49  
50  
51  
52  
53

54  
55  
56 As a result, heavily calcified lesions may be associated with a higher risk for stent restenosis and  
57  
58  
59  
60  
61  
62  
63  
64  
65

1  
2  
3 thrombosis [19, 20]. As mentioned above, calcified plaque modification before stent deployment might be  
4  
5  
6 associated with adequate stent expansion and favorable late outcomes [21].  
7

8  
9 In our study, the thickness of the calcification was a key measure for predicting lesion modification. In  
10  
11 patients with circumferential calcification (i.e., calcification angle  $>270^\circ$ ) and a calcification thickness of  
12  
13  $<535 \mu\text{m}$ , a scoring balloon angioplasty may be effective. Furthermore, the morphology of the  
14  
15  
16 calcification is another predictor for fracture of calcification. As expected, the non-convex type of  
17  
18  
19 calcified lesion could be more easily disrupted after scoring balloon angioplasty.  
20  
21  
22  
23

24  
25 The so-called “scoring balloon” has been recognized as an alternative interventional tool to pre-dilate  
26  
27 non-calcified, as well as calcified, lesions prior to stent implantation. A scoring balloon is easier to use  
28  
29 than rotational ablation, and the usefulness of the scoring balloon for heavily calcified coronary lesions is  
30  
31 well recognized [22, 23]. During balloon inflation, the scoring elements cut or crack the calcified portion  
32  
33  
34 more effectively than standard balloons without scoring elements. Lesion modification by scoring balloon  
35  
36  
37 can be more easily performed. On the other hand, use of a scoring balloon may cause coronary  
38  
39  
40 complications [24]. In a previous study, coronary calcification and use of a cutting balloon were  
41  
42  
43 associated with coronary perforation [25]. Furthermore, in vessels having an eccentric plaque, there might  
44  
45  
46 also be a risk of perforation. However, fortunately, coronary perforation did not occur in our study.  
47  
48  
49  
50  
51 Similar to a previous study [26], only 7 cases (21.8%) showed complete stent apposition. Moreover, we  
52  
53  
54 failed to deploy a coronary stent in 1 case. In this case, rotational ablation should have been performed.  
55  
56  
57  
58  
59  
60  
61  
62  
63  
64  
65

1  
2  
3 Furthermore, 3 TLRs were documented in this study. Severe calcification is still associated with an  
4  
5  
6 increased risk of adverse cardiovascular events following treatment with DES [27].  
7  
8

9  
10 In our study, OCT was used to assess calcification and lesion modification. OCT provides  
11  
12 higher-resolution imaging (10–20  $\mu\text{m}$ ) than intravascular ultrasound (IVUS, 150–200  $\mu\text{m}$ ) [8] and detects  
13  
14 calcification contours more clearly. A previous study comparing OCT, IVUS, and histological analysis  
15  
16 showed that OCT more accurately quantified the amount of calcification than IVUS. OCT-guided PCI is  
17  
18  
19 effective for heavily calcified coronary lesions.  
20  
21  
22

### 23 24 25 **Limitations** 26

27  
28 There are several limitations to this study. First, it was a single-center, retrospective study with a small  
29  
30 sample size. To address the impact of balloon size and maximal inflation pressure, far more cases are  
31  
32 needed. Second, only 1 type of scoring balloon was used for pre-dilatation. This makes the predictive  
33  
34 value of the calcification thickness and angle for lesion modification by other scoring balloons, as well as  
35  
36  
37 standard balloons, uncertain.  
38  
39  
40  
41  
42

### 43 44 45 **Conclusions** 46

47  
48 Both the thickness and the shape of the calcification are predictive of successful lesion modification  
49  
50 after scoring balloon angioplasty. A coronary plaque calcification with a thickness of  $<565 \mu\text{m}$  and a  
51  
52 non-convex shape may be disrupted better by scoring balloon angioplasty prior to stent implantation than  
53  
54  
55 other types of calcifications.  
56  
57  
58  
59  
60  
61  
62  
63  
64  
65

1  
2  
3 **Compliance with ethical standards**  
4

5  
6 **Disclosure of potential conflicts of interest**  
7

8  
9  
10 Conflict of Interests: The authors declare that they have no conflict of interest.  
11

12  
13 **Research involving human participants and/or animals**  
14

15  
16 Ethical approval: All procedures performed in this study involving human participants were in accordance  
17

18  
19 with the ethical standards of the institutional and/or national research committee and with the 1964  
20

21  
22 Helsinki declaration and its later amendments or comparable ethical standards. For this type of study  
23

24  
25 formal consent is not required.  
26

27  
28 **Informed consent**  
29

30  
31 Informed consent was obtained from all individual participants included in the study.  
32  
33  
34  
35  
36  
37

38 **References**  
39

40  
41 1. Park DW, Park SW, Park KH, Lee BK, Kim YH, Lee CW, et al. Frequency of and risk factors for stent  
42

43  
44 thrombosis after drug-eluting stent implantation during long-term follow-up. *Am J Cardiol.* 2006;  
45

46  
47 98:352–6.  
48

49  
50 2. Song HG, Kang SJ, Ahn JM, Kim WJ, Lee JY, Park DW, et al. Intravascular ultrasound assessment of  
51

52  
53 optimal stent area to prevent in-stent restenosis after zotarolimus-, everolimus-, and sirolimus-eluting  
54

55  
56 stent implantation. *Catheter Cardiovasc Interv.* 2014; 83:873–8.  
57  
58  
59  
60  
61  
62  
63  
64  
65

1  
2  
3 3. Barath P, Fishbein MC, Vari S, Forrester JS. Cutting balloon: a novel approach to percutaneous  
4  
5  
6 angioplasty. *Am J Cardiol.* 1991; 68:1249–52.  
7

8  
9  
10 4. de Ribamar Costa J Jr, Mintz GS, Carlier SG, Mehran R, Teirstein P, Sano K, et al. Nonrandomized  
11  
12 comparison of coronary stenting under intravascular ultrasound guidance of direct stenting without  
13  
14 predilation versus conventional predilation with a semi-compliant balloon versus predilation with a new  
15  
16 scoring balloon. *Am J Cardiol.* 2007; 100:812–7.  
17  
18

19  
20  
21 5. Ashida K, Hayase T, Shinmura T. Efficacy of Lacrosse NSE using the “Leopard-Crawl” technique on  
22  
23 severely calcified lesions. *J Invasive Cardiol.* 2013; 25:555–64.  
24  
25

26  
27  
28 6. Yabushita H, Bouma BE, Houser SL, Aretz HT, Jang IK, Schlerndorf KH, et al. Characterization of  
29  
30 human atherosclerosis by optical coherence tomography. *Circulation.* 2002; 106:1640–5.  
31  
32

33  
34  
35 7. Kume T, Okura H, Kawamoto T, Akasaka T, Toyota E, Watanabe N, et al. Relationship between  
36  
37 coronary remodeling and plaque characterization in patients without clinical evidence of coronary artery  
38  
39 disease. *Atherosclerosis.* 2008; 197:799–805.  
40  
41

42  
43  
44 8. Kume T, Okura H, Kawamoto T, Yamada R, Miyamoto Y, Hayashida A, et al. Assessment of the  
45  
46 coronary calcification by optical coherence tomography. *EuroIntervention.* 2011; 6:768–72.  
47  
48

49  
50  
51 9. Miyamoto Y, Okura H, Kume T, Kawamoto T, Neishi Y, Hayashida A, et al. Plaque characteristics of  
52  
53 thin-cap fibroatheroma evaluated by OCT and IVUS. *JACC Cardiovasc Imaging.* 2011; 4:638–46.  
54  
55

56  
57 10. Kobayashi Y, Okura H, Kume T, Yamada R, Kobayashi Y, Fukuhara K, et al. Impact of target lesion  
58  
59  
60  
61  
62  
63  
64  
65

1  
2  
3 coronary calcification on stent expansion. *Circ J*. 2014; 78:2209–14.  
4  
5

6 11. von Birgelen C, Mintz GS, Böse D, Baumgart D, Haude M, Wieneke H, et al. Impact of moderate  
7 lesion calcium on mechanisms of coronary stenting as assessed with three-dimensional intravascular  
8 ultrasound in vivo. *Am J Cardiol*. 2003; 92:5–10.  
9  
10  
11  
12  
13

14  
15  
16 12. Hoffmann R, Mintz GS, Popma JJ, Satler LF, Kent KM, Pichard AD, et al. Treatment of calcified  
17 coronary lesions with Palmaz-Schatz stents. An intravascular ultrasound study. *Eur Heart J*. 1998;  
18  
19  
20  
21  
22  
23 19:1224–31.  
24  
25

26  
27 13. Vavuranakis M, Toutouzas K, Stefanadis C, Chrishou C, Markou D, Toutouzas P. Stent deployment  
28 in calcified lesions: can we overcome calcific restraint with high-pressure balloon inflations? *Catheter*  
29  
30  
31  
32  
33  
34  
35  
36  
37  
38  
39  
40  
41  
42  
43  
44  
45  
46  
47  
48  
49  
50  
51  
52  
53  
54  
55  
56  
57  
58  
59  
60  
61  
62  
63  
64  
65

66  
67  
68  
69  
70  
71  
72  
73  
74  
75  
76  
77  
78  
79  
80  
81  
82  
83  
84  
85  
86  
87  
88  
89  
90  
91  
92  
93  
94  
95  
96  
97  
98  
99  
100  
101  
102  
103  
104  
105  
106  
107  
108  
109  
110  
111  
112  
113  
114  
115  
116  
117  
118  
119  
120  
121  
122  
123  
124  
125  
126  
127  
128  
129  
130  
131  
132  
133  
134  
135  
136  
137  
138  
139  
140  
141  
142  
143  
144  
145  
146  
147  
148  
149  
150  
151  
152  
153  
154  
155  
156  
157  
158  
159  
160  
161  
162  
163  
164  
165  
166  
167  
168  
169  
170  
171  
172  
173  
174  
175  
176  
177  
178  
179  
180  
181  
182  
183  
184  
185  
186  
187  
188  
189  
190  
191  
192  
193  
194  
195  
196  
197  
198  
199  
200  
201  
202  
203  
204  
205  
206  
207  
208  
209  
210  
211  
212  
213  
214  
215  
216  
217  
218  
219  
220  
221  
222  
223  
224  
225  
226  
227  
228  
229  
230  
231  
232  
233  
234  
235  
236  
237  
238  
239  
240  
241  
242  
243  
244  
245  
246  
247  
248  
249  
250  
251  
252  
253  
254  
255  
256  
257  
258  
259  
260  
261  
262  
263  
264  
265  
266  
267  
268  
269  
270  
271  
272  
273  
274  
275  
276  
277  
278  
279  
280  
281  
282  
283  
284  
285  
286  
287  
288  
289  
290  
291  
292  
293  
294  
295  
296  
297  
298  
299  
300  
301  
302  
303  
304  
305  
306  
307  
308  
309  
310  
311  
312  
313  
314  
315  
316  
317  
318  
319  
320  
321  
322  
323  
324  
325  
326  
327  
328  
329  
330  
331  
332  
333  
334  
335  
336  
337  
338  
339  
340  
341  
342  
343  
344  
345  
346  
347  
348  
349  
350  
351  
352  
353  
354  
355  
356  
357  
358  
359  
360  
361  
362  
363  
364  
365  
366  
367  
368  
369  
370  
371  
372  
373  
374  
375  
376  
377  
378  
379  
380  
381  
382  
383  
384  
385  
386  
387  
388  
389  
390  
391  
392  
393  
394  
395  
396  
397  
398  
399  
400  
401  
402  
403  
404  
405  
406  
407  
408  
409  
410  
411  
412  
413  
414  
415  
416  
417  
418  
419  
420  
421  
422  
423  
424  
425  
426  
427  
428  
429  
430  
431  
432  
433  
434  
435  
436  
437  
438  
439  
440  
441  
442  
443  
444  
445  
446  
447  
448  
449  
450  
451  
452  
453  
454  
455  
456  
457  
458  
459  
460  
461  
462  
463  
464  
465  
466  
467  
468  
469  
470  
471  
472  
473  
474  
475  
476  
477  
478  
479  
480  
481  
482  
483  
484  
485  
486  
487  
488  
489  
490  
491  
492  
493  
494  
495  
496  
497  
498  
499  
500  
501  
502  
503  
504  
505  
506  
507  
508  
509  
510  
511  
512  
513  
514  
515  
516  
517  
518  
519  
520  
521  
522  
523  
524  
525  
526  
527  
528  
529  
530  
531  
532  
533  
534  
535  
536  
537  
538  
539  
540  
541  
542  
543  
544  
545  
546  
547  
548  
549  
550  
551  
552  
553  
554  
555  
556  
557  
558  
559  
560  
561  
562  
563  
564  
565  
566  
567  
568  
569  
570  
571  
572  
573  
574  
575  
576  
577  
578  
579  
580  
581  
582  
583  
584  
585  
586  
587  
588  
589  
590  
591  
592  
593  
594  
595  
596  
597  
598  
599  
600  
601  
602  
603  
604  
605  
606  
607  
608  
609  
610  
611  
612  
613  
614  
615  
616  
617  
618  
619  
620  
621  
622  
623  
624  
625  
626  
627  
628  
629  
630  
631  
632  
633  
634  
635  
636  
637  
638  
639  
640  
641  
642  
643  
644  
645  
646  
647  
648  
649  
650  
651  
652  
653  
654  
655  
656  
657  
658  
659  
660  
661  
662  
663  
664  
665  
666  
667  
668  
669  
670  
671  
672  
673  
674  
675  
676  
677  
678  
679  
680  
681  
682  
683  
684  
685  
686  
687  
688  
689  
690  
691  
692  
693  
694  
695  
696  
697  
698  
699  
700  
701  
702  
703  
704  
705  
706  
707  
708  
709  
710  
711  
712  
713  
714  
715  
716  
717  
718  
719  
720  
721  
722  
723  
724  
725  
726  
727  
728  
729  
730  
731  
732  
733  
734  
735  
736  
737  
738  
739  
740  
741  
742  
743  
744  
745  
746  
747  
748  
749  
750  
751  
752  
753  
754  
755  
756  
757  
758  
759  
760  
761  
762  
763  
764  
765  
766  
767  
768  
769  
770  
771  
772  
773  
774  
775  
776  
777  
778  
779  
780  
781  
782  
783  
784  
785  
786  
787  
788  
789  
790  
791  
792  
793  
794  
795  
796  
797  
798  
799  
800  
801  
802  
803  
804  
805  
806  
807  
808  
809  
810  
811  
812  
813  
814  
815  
816  
817  
818  
819  
820  
821  
822  
823  
824  
825  
826  
827  
828  
829  
830  
831  
832  
833  
834  
835  
836  
837  
838  
839  
840  
841  
842  
843  
844  
845  
846  
847  
848  
849  
850  
851  
852  
853  
854  
855  
856  
857  
858  
859  
860  
861  
862  
863  
864  
865  
866  
867  
868  
869  
870  
871  
872  
873  
874  
875  
876  
877  
878  
879  
880  
881  
882  
883  
884  
885  
886  
887  
888  
889  
890  
891  
892  
893  
894  
895  
896  
897  
898  
899  
900  
901  
902  
903  
904  
905  
906  
907  
908  
909  
910  
911  
912  
913  
914  
915  
916  
917  
918  
919  
920  
921  
922  
923  
924  
925  
926  
927  
928  
929  
930  
931  
932  
933  
934  
935  
936  
937  
938  
939  
940  
941  
942  
943  
944  
945  
946  
947  
948  
949  
950  
951  
952  
953  
954  
955  
956  
957  
958  
959  
960  
961  
962  
963  
964  
965  
966  
967  
968  
969  
970  
971  
972  
973  
974  
975  
976  
977  
978  
979  
980  
981  
982  
983  
984  
985  
986  
987  
988  
989  
990  
991  
992  
993  
994  
995  
996  
997  
998  
999  
1000

152 16. Fujii K, Mintz GS, Kobayashi Y, Carlier SG, Takebayashi H, Yasuda T, et al. Contribution of stent  
153 underexpansion to recurrence after sirolimus-eluting stent implantation for in-stent restenosis. *Circulation*.  
154  
155  
156  
157  
158  
159  
160  
161  
162  
163  
164  
165  
166  
167  
168  
169  
170  
171  
172  
173  
174  
175  
176  
177  
178  
179  
180  
181  
182  
183  
184  
185  
186  
187  
188  
189  
190  
191  
192  
193  
194  
195  
196  
197  
198  
199  
200  
201  
202  
203  
204  
205  
206  
207  
208  
209  
210  
211  
212  
213  
214  
215  
216  
217  
218  
219  
220  
221  
222  
223  
224  
225  
226  
227  
228  
229  
230  
231  
232  
233  
234  
235  
236  
237  
238  
239  
240  
241  
242  
243  
244  
245  
246  
247  
248  
249  
250  
251  
252  
253  
254  
255  
256  
257  
258  
259  
260  
261  
262  
263  
264  
265  
266  
267  
268  
269  
270  
271  
272  
273  
274  
275  
276  
277  
278  
279  
280  
281  
282  
283  
284  
285  
286  
287  
288  
289  
290  
291  
292  
293  
294  
295  
296  
297  
298  
299  
300  
301  
302  
303  
304  
305  
306  
307  
308  
309  
310  
311  
312  
313  
314  
315  
316  
317  
318  
319  
320  
321  
322  
323  
324  
325  
326  
327  
328  
329  
330  
331  
332  
333  
334  
335  
336  
337  
338  
339  
340  
341  
342  
343  
344  
345  
346  
347  
348  
349  
350  
351  
352  
353  
354  
355  
356  
357  
358  
359  
360  
361  
362  
363  
364  
365  
366  
367  
368  
369  
370  
371  
372  
373  
374  
375  
376  
377  
378  
379  
380  
381  
382  
383  
384  
385  
386  
387  
388  
389  
390  
391  
392  
393  
394  
395  
396  
397  
398  
399  
400  
401  
402  
403  
404  
405  
406  
407  
408  
409  
410  
411  
412  
413  
414  
415  
416  
417  
418  
419  
420  
421  
422  
423  
424  
425  
426  
427  
428  
429  
430  
431  
432  
433  
434  
435  
436  
437  
438  
439  
440  
441  
442  
443  
444  
445  
446  
447  
448  
449  
450  
451  
452  
453  
454  
455  
456  
457  
458  
459  
460  
461  
462  
463  
464  
465  
466  
467  
468  
469  
470  
471  
472  
473  
474  
475  
476  
477  
478  
479  
480  
481  
482  
483  
484  
485  
486  
487  
488  
489  
490  
491  
492  
493  
494  
495  
496  
497  
498  
499  
500  
501  
502  
503  
504  
505  
506  
507  
508  
509  
510  
511  
512  
513  
514  
515  
516  
517  
518  
519  
520  
521  
522  
523  
524  
525  
526  
527  
528  
529  
530  
531  
532  
533  
534  
535  
536  
537  
538  
539  
540  
541  
542  
543  
544  
545  
546  
547  
548  
549  
550  
551  
552  
553  
554  
555  
556  
557  
558  
559  
560  
561  
562  
563  
564  
565  
566  
567  
568  
569  
570  
571  
572  
573  
574  
575  
576  
577  
578  
579  
580  
581  
582  
583  
584  
585  
586  
587  
588  
589  
590  
591  
592  
593  
594  
595  
596  
597  
598  
599  
600  
601  
602  
603  
604  
605  
606  
607  
608  
609  
610  
611  
612  
613  
614  
615  
616  
617  
618  
619  
620  
621  
622  
623  
624  
625  
626  
627  
628  
629  
630  
631  
632  
633  
634  
635  
636  
637  
638  
639  
640  
641  
642  
643  
644  
645  
646  
647  
648  
649  
650  
651  
652  
653  
654  
655  
656  
657  
658  
659  
660  
661  
662  
663  
664  
665  
666  
667  
668  
669  
670  
671  
672  
673  
674  
675  
676  
677  
678  
679  
680  
681  
682  
683  
684  
685  
686  
687  
688  
689  
690  
691  
692  
693  
694  
695  
696  
697  
698  
699  
700  
701  
702  
703  
704  
705  
706  
707  
708  
709  
710  
711  
712  
713  
714  
715  
716  
717  
718  
719  
720  
721  
722  
723  
724  
725  
726  
727  
728  
729  
730  
731  
732  
733  
734  
735  
736  
737  
738  
739  
740  
741  
742  
743  
744  
745  
746  
747  
748  
749  
750  
751  
752  
753  
754  
755  
756  
757  
758  
759  
760  
761  
762  
763  
764  
765  
766  
767  
768  
769  
770  
771  
772  
773  
774  
775  
776  
777  
778  
779  
780  
781  
782  
783  
784  
785  
786  
787  
788  
789  
790  
791  
792  
793  
794  
795  
796  
797  
798  
799  
800  
801  
802  
803  
804  
805  
806  
807  
808  
809  
810  
811  
812  
813  
814  
815  
816  
817  
818  
819  
820  
821  
822  
823  
824  
825  
826  
827  
828  
829  
830  
831  
832  
833  
834  
835  
836  
837  
838  
839  
840  
841  
842  
843  
844  
845  
846  
847  
848  
849  
850  
851  
852  
853  
854  
855  
856  
857  
858  
859  
860  
861  
862  
863  
864  
865  
866  
867  
868  
869  
870  
871  
872  
873  
874  
875  
876  
877  
878  
879  
880  
881  
882  
883  
884  
885  
886  
887  
888  
889  
890  
891  
892  
893  
894  
895  
896  
897  
898  
899  
900  
901  
902  
903  
904  
905  
906  
907  
908  
909  
910  
911  
912  
913  
914  
915  
916  
917  
918  
919  
920  
921  
922  
923  
924  
925  
926  
927  
928  
929  
930  
931  
932  
933  
934  
935  
936  
937  
938  
939  
940  
941  
942  
943  
944  
945  
946  
947  
948  
949  
950  
951  
952  
953  
954  
955  
956  
957  
958  
959  
960  
961  
962  
963  
964  
965  
966  
967  
968  
969  
970  
971  
972  
973  
974  
975  
976  
977  
978  
979  
980  
981  
982  
983  
984  
985  
986  
987  
988  
989  
990  
991  
992  
993  
994  
995  
996  
997  
998  
999  
1000



1  
2  
3 17. Doi H, Maehara A, Mintz GS, Yu A, Wang H, Mandinov L, et al. Impact of post-intervention minimal  
4  
5  
6  
7  
8  
9  
10  
11  
12  
13  
14  
15  
16  
17  
18  
19  
20  
21  
22  
23  
24  
25  
26  
27  
28  
29  
30  
31  
32  
33  
34  
35  
36  
37  
38  
39  
40  
41  
42  
43  
44  
45  
46  
47  
48  
49  
50  
51  
52  
53  
54  
55  
56  
57  
58  
59  
60  
61  
62  
63  
64  
65

stent area on 9-month follow-up patency of paclitaxel-eluting stents: an integrated intravascular  
ultrasound analysis from the TAXUS IV, V, VI and TAXUS ATLAS Workhorse, Long Lesion, and Direct  
Stent Trials. *JACC Cardiovasc Interv.* 2009; 2:269–75.

18. Uren NG, Schwarzacher SP, Metz JA, Lee DP, Honda Y, Yeung AC, et al. Predictors and outcomes  
of stent thrombosis: an intravascular ultrasound registry. *Eur Heart J.* 2002; 23:124–32.

19. Fujimoto H, Nakamura M, Yokoi H. Impact of calcification on the long-term outcomes of  
sirolimus-eluting stent implantation: subanalysis of the Cypher Post-Marketing Surveillance Registry.  
*Circ J.* 2012; 76:57–64.

20. Huang BT, Huang FY, Zuo ZL, Liu W, Huang KS, Liao YB, et al. Target lesion calcification and risk  
of adverse outcomes in patients with drug-eluting stents: a meta-analysis. *Herz.* 2015; 40:1097–106.

21. Kubo T, Shimamura K, Ino Y, Yamaguchi T, Matsuo Y, Shiono Y, et al. Superficial calcium fracture  
after PCI as assessed by OCT. *JACC Cardiovasc Imaging.* 2015; 8:1228–9.

22. Kawase Y, Saito N, Watanabe S, Bao B, Yamamoto E, Watanabe H, et al. Utility of a scoring balloon  
for a severely calcified lesion: bench test and finite element analysis. *Cardiovasc Interv Ther.* 2014;  
29:134–9.

23. Kang WC, Ahn TH, Han SH, Shin EK. Successful management of a resistant, focal calcified lesion  
following direct coronary stenting with a cutting balloon. *J Invasive Cardiol.* 2004; 16:725–6.

1  
2  
3 24. Auer J, Maurer E, Berent R, Mayr H, Punzengruber C, Weber T, et al. Clinical and angiographic  
4  
5  
6 outcome after cutting balloon angioplasty. *J Interv Cardiol.* 2003; 16:15–21.  
7

8  
9  
10 25. Hendry C, Fraser D, Eichhofer J, Mamas MA, Fath-Ordoubadi F, El-Omar M, et al. Coronary  
11  
12 perforation in the drug-eluting stent era: incidence, risk factors, management and outcome: the UK  
13  
14  
15 experience. *EuroIntervention.* 2012; 8:79–86.  
16  
17

18  
19 26. Im E, Kim BK, Ko YG, Shin DH, Kim JS, Choi D, et al. Incidences, predictors, and clinical outcomes  
20  
21  
22 of acute and late stent malapposition detected by optical coherence tomography after drug-eluting stent  
23  
24  
25 implantation. *Circ Cardiovasc Interv.* 2014; 7:88–96.  
26  
27

28  
29 27. Huisman J, van der Heijden LC, Kok MM, Danse PW, Jessurun GA, Stoel MG, et al. Impact of severe  
30  
31  
32 lesion calcification on clinical outcome of patients with stable angina, treated with newer generation  
33  
34  
35 permanent polymer-coated drug-eluting stents: a patient-level pooled analysis from TWENTE and  
36  
37  
38 DUTCH PEERS (TWENTE II). *Am Heart J.* 2016; 175:121–9.  
39  
40  
41  
42  
43  
44  
45  
46  
47  
48  
49  
50  
51  
52  
53  
54  
55  
56  
57  
58  
59  
60  
61  
62  
63  
64  
65

1  
2  
3 **Figure legends**  
4  
5

6 Figure 1. (a) Example of a cross-sectional coronary calcification. (b) The image shows the thicknesses of  
7 the calcifications (520, 470, and 440  $\mu\text{m}$ ), and 3 disruption sites can be seen. In this case, the coronary  
8 calcification angle was  $360^\circ$  and the shape was non-convex.  
9

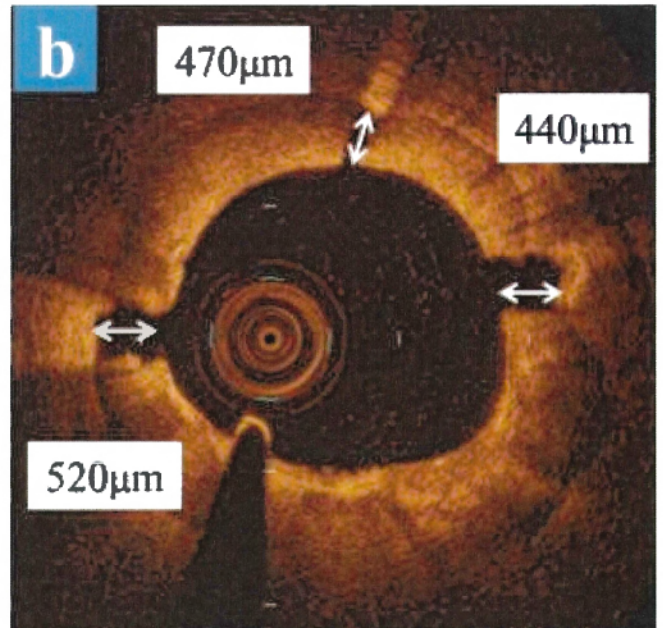
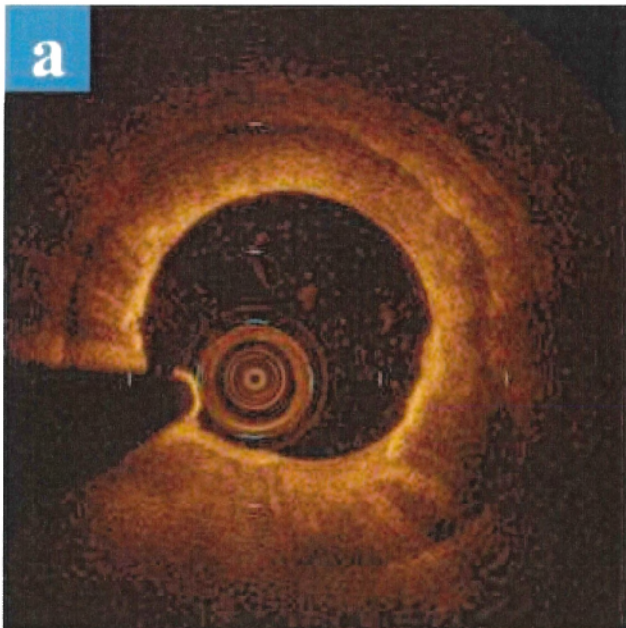
10  
11  
12  
13  
14  
15  
16 Figure 2. Prognostic value of disrupted calcification vs. non-disrupted calcification thickness in all  
17 cross-sectional OCT images (n = 203).  
18

19  
20  
21  
22 AUC = area under the curve, CI = confidence interval.  
23

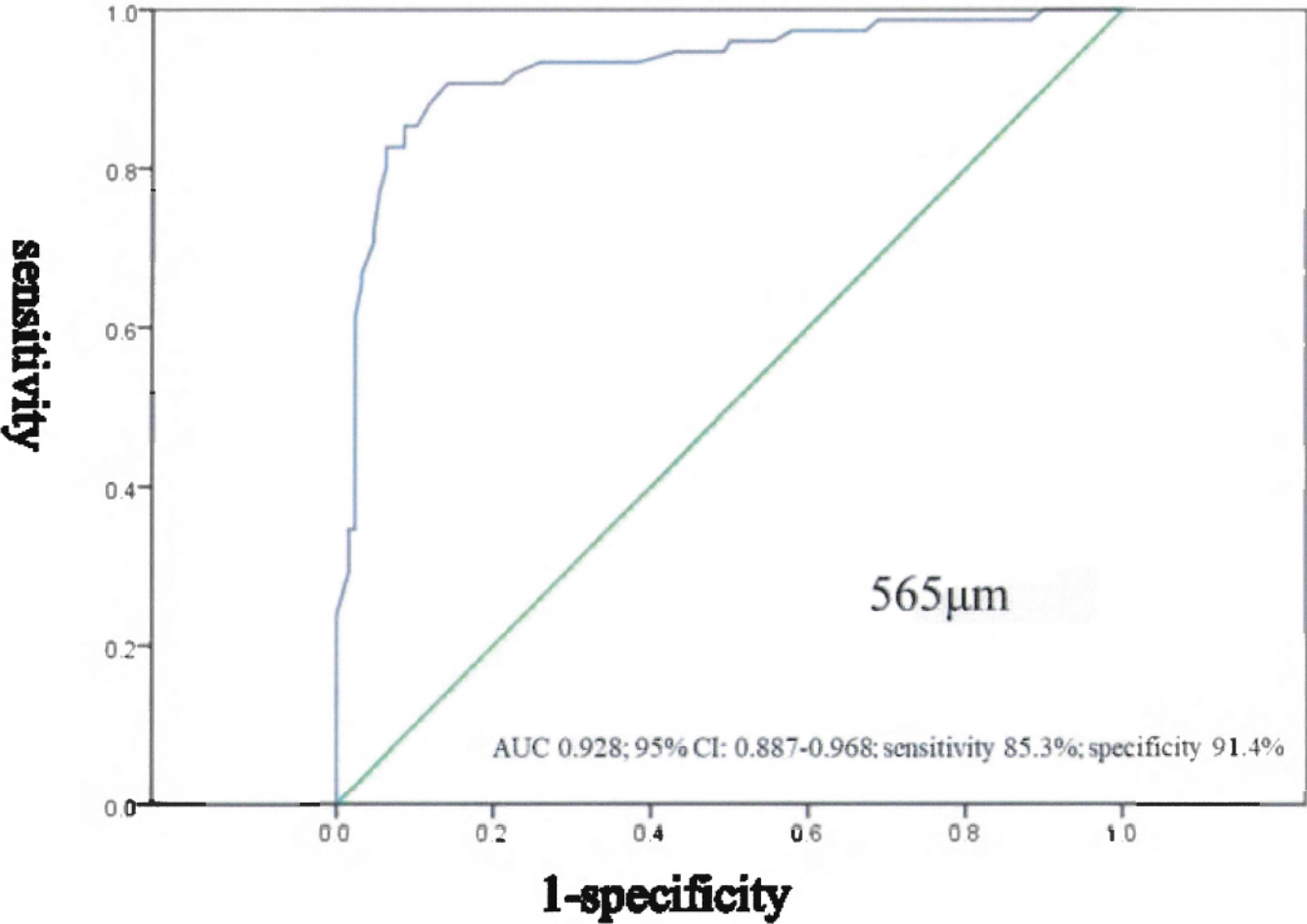
24  
25  
26 Figure 3. Prognostic value of disrupted calcification vs. non-disrupted calcification thickness in coronary  
27 angles  $>270^\circ$  (n = 101).  
28

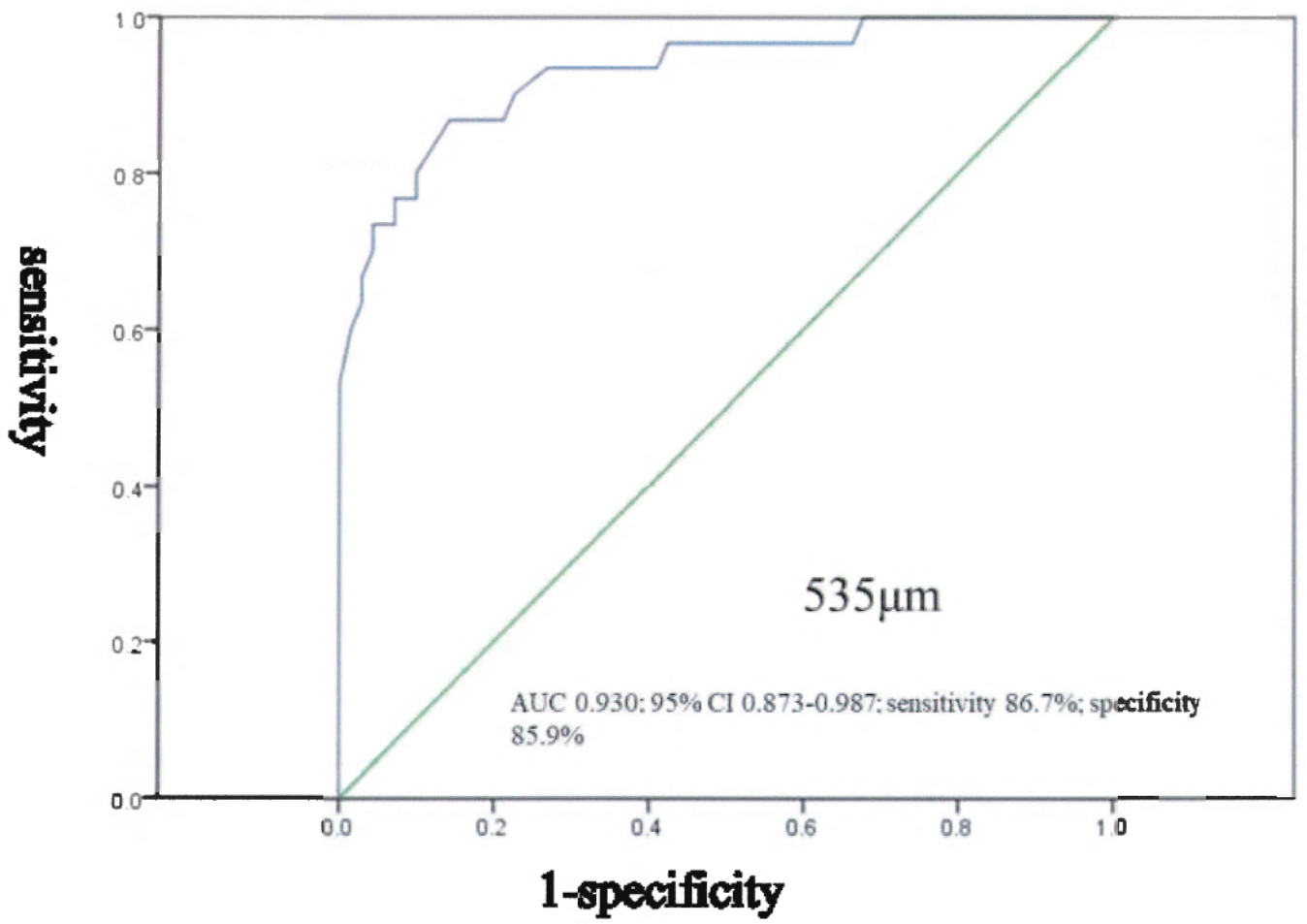
29  
30  
31  
32 AUC = area under the curve, CI = confidence interval.  
33  
34  
35  
36  
37  
38  
39  
40  
41  
42  
43  
44  
45  
46  
47  
48  
49  
50  
51  
52  
53  
54  
55  
56  
57  
58  
59  
60  
61  
62  
63  
64  
65

[Click here to access/download;Figure;Figure 1.tif](#)



[Click here to access/download:Figure:Figure 2.tif](#)





**Table 1 Patient characteristics**

---

Number of patients	32
Age, years, mean $\pm$ standard deviation	71.7 $\pm$ 9.4
Male, n (%)	27 (84.4%)
BMI, kg/m <sup>2</sup> , mean $\pm$ standard deviation	24.3 $\pm$ 3.4
Coronary risk factors	
Hypertension, n (%)	27 (84.4%)
Diabetes mellitus, n (%)	15 (46.9%)
Dyslipidemia, n (%)	28 (87.5%)
Smoker, n (%)	22 (68.8%)
Hemodialysis, n (%)	4 (12.5%)

---

BMI, body mass index

**Table 2 Angiography and procedure characteristics**

---

Target vessel	
RCA, n (%)	4 (12.5%)
LAD, n (%)	27 (84.4%)
LCX, n (%)	1 (3.1%)
Scoring balloon	
Balloon diameter, mm	2.61 ± 0.30
Pressure, atm	11.9 ± 3.2
Stent	
Stent delivery success, n (%)	31 (96.9 %)
Mean stent diameter, mm	2.81 ± 0.28
Mean total stent length, mm	36.7 ± 18.4
Mean number of stents	1.4 ± 0.61
Post-dilatation pressure, atm	17.2 ± 4.5

---



---

Coronary complication

Coronary perforation 0 (0%)

DES type

Everolimus, n (%) 39 (86.6%)

Biolimus A9, n (%) 4 (8.8%)

Zotarolimus, n (%) 2 (4.4%)

---

RCA, right coronary artery; LAD, left anterior descending artery; LCX, left circumflex artery; DES,

drug-eluting stent

**Table 3 Optical coherence tomography results comparing between disrupted and non-disrupted**

**sites**

	Disrupted group	Non-disrupted group	p-Value
Number of sites	117	55	
Calcification thickness, mm	0.35 ± 0.14	0.79 ± 0.13	<0.001
Calcification angle, degree	256.3 ± 84.5	232.7 ± 74.0	0.08
Convex shape of calcification, %	4.3	21.8	0.001

**Table 4 Optical coherence tomography results of minimal lumen area sites (N = 32)**

	Disrupted group (n = 26)	Non-disrupted group (n = 6)	p-Value
<b>Before lesion modification</b>			
Minimal lumen diameter, mm	1.04 ± 0.15	1.13 ± 0.17	0.19
Minimal lumen area, mm <sup>2</sup>	1.20 ± 0.26	1.62 ± 0.56	0.008
Calcification thickness, mm	0.38 ± 0.17	0.79 ± 0.19	<0.001
Longitudinal length of calcification, mm	18.2 ± 13.2	12.2 ± 8.3	0.31
Calcification angle, degree	274.6 ± 74.0	243.3 ± 99.9	0.39
Convex shape of calcification, n (%)	1 (3.85)	2 (33.3)	0.05

---

**After lesion modification**

Minimal lumen diameter, mm	2.07 ± 0.06	1.97 ± 0.13	0.46
Minimal lumen area, mm <sup>2</sup>	4.19 ± 1.05	3.70 ± 1.27	0.32
Incomplete stent apposition, n (%)	19 (73)	6 (100)	0.09

---