



# Dexamethasone added to levobupivacaine prolongs the duration of interscalene brachial plexus block and decreases rebound pain after arthroscopic rotator cuff repair

Shuzo Morita, MD<sup>a,\*</sup>, Naomi Oizumi, MD, PhD<sup>b</sup>, Naoki Suenaga, MD, PhD<sup>b</sup>, Chika Yoshioka, MD, PhD<sup>c</sup>, Shintaro Yamane, MD, PhD<sup>c</sup>, Yasuhito Tanaka, MD, PhD<sup>d</sup>

<sup>a</sup>Department of Orthopedic Surgery, Otemae Hospital, Osaka, Japan

<sup>b</sup>Upper Extremity Center of Joint Replacement and Endoscopic Surgery, Hokushin Orthopedic Hospital, Sapporo, Hokkaido, Japan

<sup>c</sup>Upper Extremity Center of Joint Replacement and Endoscopic Surgery, Hokushin Higashi Orthopedic Hospital, Sapporo, Hokkaido, Japan

<sup>d</sup>Department of Orthopedic Surgery, Nara Medical University, Nara, Japan

**Background:** It has been reported that the addition of dexamethasone to interscalene brachial plexus block (ISBPB) prolongs the duration of the block effect. However, there have been no studies focusing on the effects of dexamethasone on rebound pain after the block effect has worn off. The aim of this study was to investigate the effect on postoperative pain when dexamethasone was added to ISBPB for arthroscopic rotator cuff repair (ARCR).

**Methods:** In this multicenter, single-blinded, and randomized controlled study, 54 patients (33 males, 21 females) who received ARCR were randomly assigned to group L (ISBPB with 20 cc of 0.25% levobupivacaine; 21 patients) or group LD (ISBPB with 20 cc of 0.25% levobupivacaine + 3.3 mg dexamethasone; 33 patients). The primary outcome was the visual analog scale (VAS) for pain after the block effect had worn off. Secondary outcomes were the duration of analgesia, the time to the first request for additional analgesic, the number of additional doses of analgesic, and complications.

**Results:** The VAS scores on postoperative days 0 and 1 were significantly lower in group LD than group L ( $P = .005, .035$ ). This indicated that the rebound pain was relieved in group LD. After postoperative day 1, there was no significant difference in VAS score ( $P = .43$  and  $.19$  for days 2 and 3, respectively). The duration of analgesia was significantly longer in group LD than group L ( $P < .001$ ). The time to the first request for additional analgesic was significantly longer in group LD than group L ( $P < .001$ ). The number of additional doses of analgesic was significantly lower in group LD ( $P < .001$ ).

**Conclusion:** In ARCR, the addition of dexamethasone to levobupivacaine not only prolongs the duration of ISBPB but also relieves rebound pain after the block effect wears off.

**Level of evidence:** Level I; Randomized Controlled Trial; Treatment Study

© 2020 Journal of Shoulder and Elbow Surgery Board of Trustees. All rights reserved.

**Keywords:** Interscalene brachial plexus block; dexamethasone; arthroscopic rotator cuff repair; postoperative analgesia; rebound pain; shoulder surgery

The study protocol was reviewed and approved by institutional review board at Hokushin Orthopedic Hospital (no. 1801).

\*Reprint requests: Shuzo Morita, MD, 1-5-34, Otemae, Chuo-ku, Osaka 540-0008, Japan.

E-mail address: [shuzo0921@gmail.com](mailto:shuzo0921@gmail.com) (S. Morita).

Shoulder surgery often results in severe postoperative pain, regardless of whether the procedure is performed via an open or arthroscopic approach.<sup>9,16,25</sup> It is, therefore, extremely important to manage postoperative pain to minimize the perioperative use of opioids and other analgesics and to improve patient satisfaction. To this end, several different modalities such as peripheral nerve block (PNB), subacromial or intra-articular infiltration of local anesthetic, and administration of opioid or nonopioid analgesics are used for intensive postoperative pain management.<sup>4,14,19,21,22,33,35</sup> Among these modalities, interscalene brachial plexus block (ISBPB) is widely used for pain control for shoulder surgery and is applied as single-shot or continuous ISBPB.<sup>14,18,21</sup> Although continuous ISBPB provides prolonged analgesia, insertion and fixation of the catheter in an appropriate position are technically challenging,<sup>11</sup> and the procedure is associated with the risk of adverse events such as inadequate analgesia, catheter malposition, and accidental catheter removal.<sup>5,31</sup> On the other hand, single-shot ISBPB is relatively easy to perform and offers temporary relief of postoperative pain, which can reduce the requirement for perioperative opioids or other postoperative analgesics.<sup>10,13,35</sup> However, the analgesic effects of single-shot ISBPB are short lived, and patients often complain of severe pain after the block effect wears off.<sup>1,11,17,23,24,26</sup>

Recently, we reviewed many studies in which dexamethasone was administered in addition to local anesthetics to prolong the duration of the analgesic effect of single-shot PNB.<sup>8,9,14,16,20,22,27,29,30</sup> Although this approach addresses the limited effect duration of local anesthetics, the efficacy of the addition of dexamethasone for intense pain in the first few hours after the effects of ISBPB subside (rebound pain)<sup>1,17,23,24,26</sup> has not yet been investigated.

The aim of this study was to compare postoperative pain after arthroscopic rotator cuff repair (ARCR) between patients who received single-shot ISBPB without dexamethasone and those who received single-shot ISBPB with dexamethasone.

We hypothesized that the addition of dexamethasone to ISBPB would prolong the duration of analgesia and reduce rebound pain.

## Materials and methods

This study was a multicenter, single-blinded, and randomized controlled trial. Written informed consent was obtained from patients who were scheduled to undergo ARCR with single-shot ISBPB under general anesthesia. The participating institutions included 2 private orthopedic hospitals.

A total of 54 consecutive patients who received ARCR from April to August 2018 were eligible to participate in the study. Patients were excluded from the analysis if they had diabetes mellitus, allergy to levobupivacaine or dexamethasone, surgery on both shoulders, or inability to answer questions about postoperative status due to dementia or psychiatric disease.

## Randomization and blinding

The procedure of ISBPB was performed by 1 of 5 anesthesiologists. Two anesthesiologists performed ISBPB using local anesthetic only, whereas 3 performed ISBPB with dexamethasone. The allocation of anesthesiologists to procedure was determined at the start of the study. Precise information regarding the administered drugs was not provided to patients. Patients were assigned to anesthesiologists automatically by the day and time of surgery.

## Group LD

Patients in group LD received single-shot ISBPB with 20 cc of 0.25% levobupivacaine (Maruishi Pharmaceutical, Osaka, Japan) plus 3.3 mg of dexamethasone (Aspen Japan, Tokyo, Japan).

## Group L

Patients in group L received single-shot ISBPB with 20 cc of 0.25% levobupivacaine.

## Anesthetic techniques and operative procedures

All patients were placed in the supine position and received standardized general anesthesia using intravenous propofol, remifentanyl, and rocuronium, and supplemental oxygen and air administered via laryngeal mask airway. The anesthesiologist performed ISBPB under general anesthesia with ultrasound guidance (Venue 40; GE Healthcare Japan, Tokyo, Japan). The brachial plexus nerve between the anterior and middle scalene was detected by the ultrasound scan of the cervical region. After sterilization of the aspiration point, the agent was injected under ultrasound guidance using a 23-gauge long needle. The type of agent was recorded by the anesthesiologist, and then ARCR was performed in the same manner by 1 of 4 orthopedic surgeons. Acromioplasty was performed in all cases. Small or medium cuff tear (which was evaluated intraoperatively using arthroscopy and classified using the Cofield classification<sup>7</sup>) was fixed by suture bridge repair<sup>28</sup> and large or massive tear by surface-holding repair.<sup>34</sup>

## Postoperative management and evaluations

After surgery and general anesthesia, patients were transferred to the general ward. Patients could request rescue analgesics (suppository [diclofenac sodium 25 or 50 mg], intravenous drip [flurbiprofen axetil 50 mg], or oral [loxoprofen 60 mg] administration of nonsteroidal anti-inflammatory drugs, or intramuscular injection of 15 mg pentazocine) at any time. Postoperatively, basic analgesics (loxoprofen 180 mg/d or acetaminophen 1200 mg/d if the patient had bronchial asthma or was allergic to loxoprofen) were administered after each meal from postoperative day 1. No oral or intravenous opioids were used during the postoperative period. Patients completed a questionnaire about the time of the first appearance of pain at the surgical site, level of pain 6 hours after ISBPB, and maximum pain on the day of surgery and postoperative days 1, 2, and 3. We used the visual analog scale (VAS) to confirm the severity of postoperative pain. Nurses recorded the time of the first request for analgesic and the number of additional doses of analgesic during the 4 days after surgery.

The duration of analgesia was considered to be indicated by the time interval between the administration of ISBPB and the time at which postoperative pain was first experienced. Complications related to ISBPB such as persistent nerve palsy, infection, and hematoma were also evaluated.

The primary outcome was the VAS for pain after the block effect had worn off. Secondary outcomes included the duration of analgesia, the time to the first request for additional analgesic, the number of additional doses of analgesic, and complications.

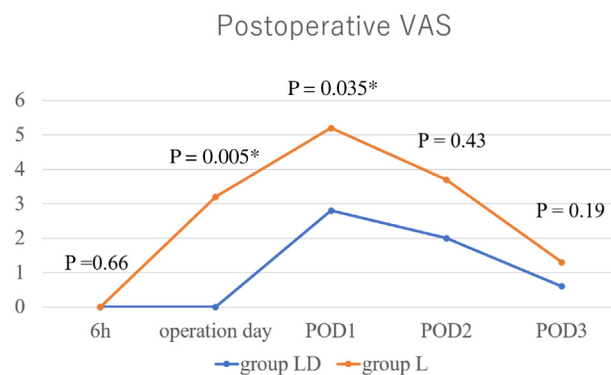
## Statistical analysis

All statistical analyses were performed with EZR (Saitama Medical Center, Jichi Medical University, Saitama, Japan), which is a graphical user interface for R (The R Foundation for Statistical Computing, Vienna, Austria). More precisely, it is a modified version of R commander designed to add statistical functions frequently used in biostatistics. Continuous variables were expressed as mean  $\pm$  standard deviation or median [interquartile range]. Categorical variables were analyzed using the  $\chi^2$  or Fisher's exact tests. Age, body mass index, VAS score, and the number of additional doses of analgesic were compared between the 2 groups using the Mann-Whitney *U* test. The duration of analgesia and the time to the first request for additional analgesic were analyzed by Kaplan-Meier survival analysis with the log-rank test. Data were censored 84 hours after ISBPB. Patients who did not report any pain were censored for overall survival analysis. The level of significance was set at  $P < .05$ .

## Results

Among the 54 patients who received ARCR between April and August 2018, 21 were randomized to group L and 33 were randomized to group LD. There were no significant differences in age, sex, or size of the torn rotator cuff between the 2 groups (Table I).

The VAS score for pain was not significantly different between the 2 groups at 6 hours postoperatively (Fig. 1, Table II). However, the maximum VAS scores for pain on



**Figure 1** The line plot of postoperative VAS for pain (median) in the 2 study groups. Group L received interscalene brachial plexus block with 0.25% levobupivacaine (20 cc). Group LD received interscalene brachial plexus block with 0.25% levobupivacaine (20 cc) + 3.3 mg dexamethasone. VAS, visual analog scale; POD, postoperative day. \* Statistically significant ( $P < .05$ ).

the day of surgery and postoperative day 1 were significantly lower in group LD than group L. On days 2 and 3, this difference was no longer significant. The maximum VAS for pain over the 4 postoperative days was significantly lower in group LD than group L.

The duration of analgesia was significantly longer in group LD than group L (median survival time of group LD, 24.0 hours and group L, 14.5 hours) ( $P < .0001$ ) (Table II, Fig. 2).

The time to the first request for additional analgesic was significantly longer in group LD than group L (mean survival time of group LD, 52.1 hours and group L, 27.8 hours) ( $P < .0001$ ) (Fig. 3). The percentage of patients who did not request additional analgesic was 39.4% and 14.3% in groups LD and L, respectively ( $P = .096$ ).

The number of additional doses of analgesic during the 4 postoperative days was significantly lower in group LD than group L (Table II).

No postoperative complications related to ISBPB were observed.

## Discussion

In this multicenter, single-blinded, and randomized controlled study, we found that the addition of dexamethasone to ISBPB significantly reduced the postoperative pain on the day of surgery as well as on postoperative day 1, although this effect was not observed on postoperative days 2 and 3.

Many previous studies have investigated the effect of the addition of dexamethasone to PNB with regard to postoperative pain. Several of these have reported postoperative pain to be reduced by the addition of dexamethasone;<sup>2,20</sup> however, these studies only evaluated pain during the time that PNB was maintained, and the impact of dexamethasone on pain experienced after the block effect had worn off has not been reported.

**Table I** Patients' demographic variables

Variables	Group L	Group LD	<i>P</i> value
Age (yr)	62.1 $\pm$ 11.0	63.6 $\pm$ 10.4	.71
Sex (male/female)	11/10	22/11	.44
Body mass index (kg/m <sup>2</sup> )	24.5 $\pm$ 1.6	24.6 $\pm$ 0.6	1
Size of tear (small, medium/large, massive)	18/3	29/4	1

Continuous data are presented as mean  $\pm$  standard deviation, and categorical data as number.

Group L received interscalene brachial plexus block with 0.25% levobupivacaine (20 cc). Group LD received interscalene brachial plexus block with 0.25% levobupivacaine (20 cc) + 3.3 mg dexamethasone.

**Table II** Postoperative VAS for pain, duration of analgesia, and additional usage of analgesic

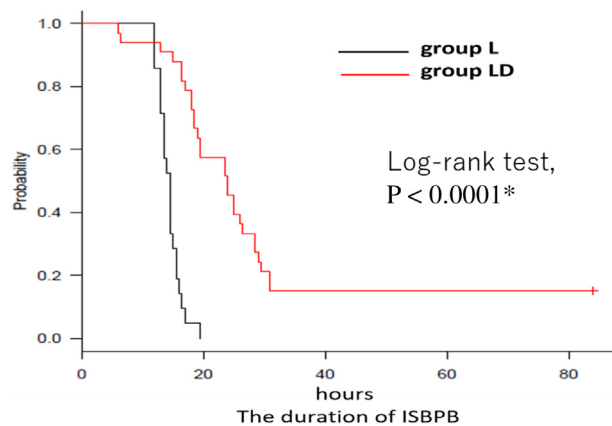
	Group L	Group LD	P value
VAS for pain (6 h after ISBPB)	0 [0-0]	0 [0-0]	.66
VAS for pain (maximum of operation day)	3.2 [0-7.5]	0 [0-1.3]	.005*
VAS for pain (maximum POD1)	5.2 [3.7-7.3]	2.8 [1.6-5]	.035*
VAS for pain (maximum POD2)	3.7 [1.4-5]	2.0 [1.2-4.8]	.43
VAS for pain (maximum POD3)	1.3 [0.5-3]	0.6 [0-2.4]	.19
VAS for pain (maximum for 4 d)	7.1 [4.1-8.6]	4.6 [1.7-7]	.02*
Duration of analgesia (h)	14.5 [13-15]	24.0 [18.5-26.5]	<.0001*
Number of additional doses of analgesic	3 [2-4]	1 [0-2]	.0016*

VAS, visual analog scale; ISBPB, interscalene brachial plexus block; POD, postoperative day.

Continuous variables were expressed as median [interquartile range] except the duration of analgesia, which is expressed as median survival time [95% confidence interval]. Group L received interscalene brachial plexus block with 0.25% levobupivacaine (20 cc). Group LD received interscalene brachial plexus block with 0.25% levobupivacaine (20 cc) + 3.3 mg dexamethasone.

\* Statistically significant ( $P < .05$ ).

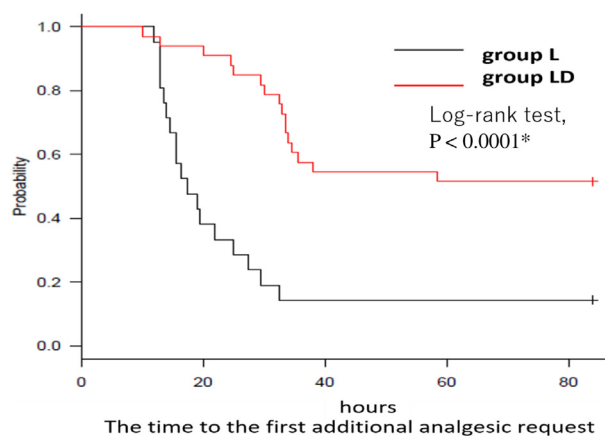
Other studies have reported reduced pain after the analgesic effects of PNB have worn off.<sup>16,18</sup> Although these studies do not discuss the effect of the addition of dexamethasone on rebound pain, these results are consistent with our findings. In the present study, on the day of surgery, the maximum VAS for pain in group LD was significantly lower than that in group L due to the residual effects of ISBPB by dexamethasone. On postoperative day 1, even when the effect of the block had worn off for both groups, the maximum VAS for pain was still significantly lower among patients who had received dexamethasone. Patients who received local anesthetic only reported a maximum pain score of VAS point 5 on postoperative day 1; this increase in pain represents rebound pain. After postoperative day 1, the significant difference in pain scores between the 2 groups disappeared as postoperative pain itself was gradually alleviated. Therefore, we found that controlling severe pain is highly important until postoperative day 1 to



**Figure 2** Kaplan-Meier survival plot showing the duration of interscalene brachial plexus block (ISBPB) in the 2 study groups. Group L received ISBPB with 0.25% levobupivacaine (20 cc). Group LD received ISBPB with 0.25% levobupivacaine (20 cc) + 3.3 mg dexamethasone. Median survival time: group LD = 24.0 hours, group L = 14.5 hours. \* Statistically significant ( $P < .05$ ).

relieve rebound pain. Taken together, the results of this study provide sufficient evidence that dexamethasone relieves pain beyond the duration of the analgesic effect of PNB. Thus, it is possible that dexamethasone can effectively attenuate rebound pain.

According to an in vivo animal study, which used a mouse sciatic nerve block model, rebound hyperalgesia induced by bupivacaine can be prevented by the administration of perineural dexamethasone through the prevention of bupivacaine-induced Schwann cell degeneration.<sup>3</sup> It is possible that perineural dexamethasone could prevent the transient neurotoxicity of bupivacaine, thus guarding against demyelination and Schwann cell degeneration, resulting in the reported antinociceptive and antineurotoxic effects in the mouse sciatic model. Perineural administration of dexamethasone in addition to a clinical



**Figure 3** Kaplan-Meier survival plot showing the time to the first request for additional analgesic in the 2 study groups. Group L received interscalene brachial plexus block with 0.25% levobupivacaine (20 cc). Group LD received interscalene brachial plexus block with 0.25% levobupivacaine (20 cc) + 3.3 mg dexamethasone. Median survival time: group LD = 52.1 hours, group L = 27.8 hours. \* Statistically significant ( $P < .05$ ).

concentration of bupivacaine could prolong the duration of sensory and motor blockade of the sciatic nerve, as well as preventing bupivacaine-induced reversible neurotoxicity and short-term rebound hyperalgesia after resolution of the block. The hyperalgesia described in that study is likely to be correlated with the clinically important phenomenon of rebound pain; although the mouse study involved different anesthetics, the results are consistent with our findings, which suggest the efficacy of dexamethasone for alleviation of postoperative pain.

Although the underlying mechanism of the prolongation of PNB and pain relief by dexamethasone is not fully understood, it is considered to involve direct block of transmission in nociceptive C-fibers,<sup>15</sup> perineural vasoconstriction with concomitant slower absorption of local anesthetics,<sup>32</sup> and systemic antiinflammatory effects. There is currently no consensus as to whether dexamethasone in PNB exerts a systemic antiinflammatory effect. Several studies have demonstrated that the intravenous and perineural administration of dexamethasone cause equivalent increases in the duration of the analgesic effect of single-shot PNB with local anesthetic.<sup>2,9,30</sup> It is likely that the blood concentrations of dexamethasone will differ according to the administration method; therefore, there is a possibility that the mechanism of action of dexamethasone also varies according to administration route. Castillo et al<sup>6</sup> reported that dexamethasone injected to 1 sciatic nerve of rats does not prolong blockade from bupivacaine microspheres injected to the contralateral nerve. Consequently, it is difficult to consider that dexamethasone added to PNB exerts a systemic anti-inflammatory effect stronger than the local effect. A recent *in vivo* investigation has demonstrated the antinociceptive and antineurotoxic effects of dexamethasone in a mouse sciatic nerve block model.<sup>3</sup> Thus, it can be presumed that dexamethasone prolongs the duration of analgesia in PNB by inducing vasoconstriction with concomitant slower absorption, relieving pain severity by blocking nerve transmission and preventing neurotoxic effects. However, because high doses of local dexamethasone may produce systemic effects, further investigation should be conducted to confirm this suggestion.

In summary, the addition of dexamethasone to local anesthetic has an advantage of prolonging the duration of analgesia and relieving rebound pain after the effect of PNB wears off. These effects can also reduce the requirement for additional analgesics. The impact of this strategy extends to various indirect benefits, including improvements in postoperative patient satisfaction and overall reduction of medical costs. Another noteworthy point described in the present study is that no opioids are required to sustain postoperative analgesia. The administration of opioids as postoperative analgesia is often accompanied by concerns relating to respiratory depression, sedation, nausea, vomiting, and so on.<sup>36</sup> Furthermore, the social issue of an opioid epidemic has been reported due to over-prescribing and misuse of these narcotics.<sup>12</sup> The addition of dexamethasone to local anesthetic represents a beneficial

strategy toward the goal of decreasing postoperative opioid use through prolonged analgesic effects and relief of rebound pain.

The present study has some limitations that should be acknowledged. First, 4 different surgeons performed the surgeries, and ISBPB was performed by 5 different anesthesiologists. We cannot rule out the possibility that the skill level and general approach of each surgeon and anesthesiologist impacted the findings and extent of postoperative pain experienced by individual patients. Second, postoperative pain and the VAS rating for pain are subjective; thus, a patient's rating of pain levels may not be representative. It has been reported that mental illness, comorbidities, and other factors affect the postoperative pain of shoulder arthroplasty.<sup>23</sup> These factors or sleep status may have affected the results. Third, the analgesics used were not the same for each patient. Patients were generally administered loxoprofen; however, those with bronchial asthma or allergies to loxoprofen were given acetaminophen and were unable to use diclofenac as additional medication. This may have affected the duration of analgesia, the amount of analgesic required, and postoperative pain. Fourth, the duration of analgesia is different to the real duration of the analgesic effect because some patients do not experience postoperative pain due to the effect of ISBPB and analgesics. Fifth, 68 patients would need to be included in each of the 2 study groups to achieve a statistical power of 80% for the VAS score. The limited sample size of this study thus reduces the impact of the final conclusions. Finally, we did not evaluate preoperative shoulder pain. Previous studies have reported that preoperative pain affects postoperative pain in shoulder surgery, which may have influenced the VAS scores in the present study.<sup>23,37</sup>

## Conclusion

The addition of dexamethasone to ISBPB not only prolongs the duration of analgesia but also relieves rebound pain after the block effect wears off, thus decreasing the total usage of analgesics. This can be an option to minimize the disadvantages of single-shot ISBPB.

## Disclaimer

The authors, their immediate families, and any research foundations with which they are affiliated have not received any financial payments or other benefits from any commercial entity related to the subject of this article.

## References

1. Abdallah FW, Halpern SH, Aoyama K, Brull R. Will the real benefits of single-shot interscalene block please stand up? A systematic review

- and meta-analysis. *Anesth Analg* 2015;120:1114-29. <https://doi.org/10.1213/ane.0000000000000688>
2. Abdallah FW, Johnson J, Chan V, Murgatroyd H, Ghafari M, Ami N, et al. Intravenous dexamethasone and perineural dexamethasone similarly prolong the duration of analgesia after supraclavicular brachial plexus block: a randomized, triple-arm, double-blind, placebo-controlled trial. *Reg Anesth Pain Med* 2015;40:125-32. <https://doi.org/10.1097/AAP.0000000000000210>
  3. An K, Elkassabany NM, Liu J. Dexamethasone as adjuvant to bupivacaine prolongs the duration of thermal antinociception and prevents bupivacaine-induced rebound hyperalgesia via regional mechanism in a mouse sciatic nerve block model. *PLoS One* 2015;10:e0123459. <https://doi.org/10.1371/journal.pone.0123459>
  4. Boss AP, Maurer T, Seiler S, Aeschbach A, Hintermann B, Strebel S. Continuous subacromial bupivacaine infusion for postoperative analgesia after open acromioplasty and rotator cuff repair: preliminary results. *J Shoulder Elbow Surg* 2004;13:630-4. <https://doi.org/10.1016/j.jse.2004.04.005>
  5. Bryan NA, Swenson JD, Greis PE, Burks RT. Indwelling interscalene catheter use in an outpatient setting for shoulder surgery: technique, efficacy, and complications. *J Shoulder Elbow Surg* 2007;16:388-95. <https://doi.org/10.1016/j.jse.2006.10.012>
  6. Castillo J, Curley J, Hotz J, Uezono M, Tigner J, Chasin M, et al. Glucocorticoids prolong rat sciatic nerve blockade in vivo from bupivacaine microspheres. *Anesthesiology* 1996;85:1157-66.
  7. Cofield RH. Subscapular muscle transposition for repair of chronic rotator cuff tears. *Surg Gynecol Obstet* 1982;154:667-72.
  8. Cummings KC 3rd, Napierkowski DE, Parra-Sanchez I, Kurz A, Dalton JE, Brems JJ, et al. Effect of dexamethasone on the duration of interscalene nerve blocks with ropivacaine or bupivacaine. *Br J Anaesth* 2011;107:446-53. <https://doi.org/10.1093/bja/aer159>
  9. Desmet M, Braems H, Reynvoet M, Plasschaert S, Van Cauwelaert J, Pottel H, et al. I.V. and perineural dexamethasone are equivalent in increasing the analgesic duration of a single-shot interscalene block with ropivacaine for shoulder surgery: a prospective, randomized, placebo-controlled study. *Br J Anaesth* 2013;111:445-52. <https://doi.org/10.1093/bja/aet109>
  10. Fredrickson MJ, Ball CM, Dalgleish AJ. Analgesic effectiveness of a continuous versus single-injection interscalene block for minor arthroscopic shoulder surgery. *Reg Anesth Pain Med* 2010;35:28-33. <https://doi.org/10.1097/AAP.0b013e3181c771bd>
  11. Fredrickson MJ, Krishnan S, Chen CY. Postoperative analgesia for shoulder surgery: a critical appraisal and review of current techniques. *Anaesthesia* 2010;65:608-24. <https://doi.org/10.1111/j.1365-2044.2009.06231.x>
  12. Hagemeyer NE. Introduction to the opioid epidemic: the economic burden on the healthcare system and impact on quality of life. *Am J Manag Care* 2018;24(suppl):S200-6.
  13. Hughes MS, Matava MJ, Wright RW, Brophy RH, Smith MV. Interscalene brachial plexus block for arthroscopic shoulder surgery: a systematic review. *J Bone Joint Surg Am* 2013;95:1318-24. <https://doi.org/10.2106/JBJS.L.0116>
  14. Huynh TM, Marret E, Bonnet F. Combination of dexamethasone and local anaesthetic solution in peripheral nerve blocks: a meta-analysis of randomised controlled trials. *Eur J Anaesthesiol* 2015;32:751-8. <https://doi.org/10.1097/EJA.0000000000000248>
  15. Johannsson A, Hao J, Sjolund B. Local corticosteroid application blocks transmission in normal nociceptive c-fibers. *Acta Anaesthesiol Scand* 1990;34:335-8.
  16. Kawanishi R, Yamamoto K, Tobetto Y, Nomura K, Kato M, Go R, et al. Perineural but not systemic low-dose dexamethasone prolongs the duration of interscalene block with ropivacaine: a prospective randomized trial. *Local Reg Anesth* 2014;7:5-9. <https://doi.org/10.2147/LRA.S59158>
  17. Kim J, Koh HJ, Kim DK, Lee H, Kwon K, Lee K, et al. Interscalene brachial plexus bolus block versus patient-controlled interscalene indwelling catheter analgesia for the first 48 hours after arthroscopic rotator cuff repair. *J Shoulder Elbow Surg* 2018;27:1243-50. <https://doi.org/10.1016/j.jse.2018.02.048>
  18. Kim YJ, Lee GY, Kim DY, Kim CH, Baik HJ, Heo S. Dexamethasone added to levobupivacaine improves postoperative analgesia in ultrasound guided interscalene brachial plexus blockade for arthroscopic shoulder surgery. *Korean J Anesthesiol* 2012;62:130-4. <https://doi.org/10.4097/kjae.2012.62.2.130>
  19. Lee HJ, Kim YS, Park I, Ha DH, Lee JH. Administration of analgesics after rotator cuff repair: a prospective clinical trial comparing glenohumeral, subacromial, and a combination of glenohumeral and subacromial injections. *J Shoulder Elbow Surg* 2015;24:663-8. <https://doi.org/10.1016/j.jse.2014.012.009>
  20. Mamoru T, Marchiori P, Schuelter-Trevisol F, José D. Dexamethasone as a ropivacaine adjuvant for ultrasound-guided interscalene brachial plexus block: a randomized, double-blinded clinical trial. *J Clin Anesth* 2017;38:133-6. [10.1016/j.jclinane.2017.02.004](https://doi.org/10.1016/j.jclinane.2017.02.004)
  21. Misamore G, Webb B, McMurray S, Sallay P. A prospective analysis of interscalene brachial plexus blocks performed under general anesthesia. *J Shoulder Elbow Surg* 2011;20:308-14. <https://doi.org/10.1016/j.jse.2010.04.043>
  22. Movafegh A, Razazian M, Hajimaohamadi F, Meysamie A. Dexamethasone added to lidocaine prolongs axillary brachial plexus blockade. *Anesth Analg* 2006;102:263-7. [10.1213/01.ane.0000189055.06729.0a](https://doi.org/10.1213/01.ane.0000189055.06729.0a)
  23. Namdari S, Nicholson T, Abboud J, Lazarus M, Steinberg D, Williams G. Randomized controlled trial of interscalene block compared with injectable liposomal bupivacaine in shoulder arthroplasty. *J Bone Joint Surg Am* 2017;99:550-6. <https://doi.org/10.2106/jbjs.16.00296>
  24. Namdari S, Nicholson T, Abboud J, Lazarus M, Steinberg D, Williams G. Interscalene block with and without intraoperative local infiltration with liposomal bupivacaine in shoulder arthroplasty: a randomized controlled trial. *J Bone Joint Surg Am* 2018;100:1373-8. <https://doi.org/10.2106/JBJS.17.01416>
  25. Oh JH, Kim WS, Kim JY, Gong HS, Rhee K. Continuous intralesional infusion combined with interscalene block was effective for postoperative analgesia after arthroscopic shoulder surgery. *J Shoulder Elbow Surg* 2007;16:295-9. <https://doi.org/10.1016/j.jse.2006.04.015>
  26. Okoroa KR, Lynch JR, Keller RA, Korona J, Amato C, Rill B, et al. Liposomal bupivacaine versus interscalene nerve block for pain control after shoulder arthroplasty: a prospective randomized trial. *J Shoulder Elbow Surg* 2016;25:1742-8. <https://doi.org/10.1016/j.jse.2016.05.007>
  27. Pani N, Routray SS, Mishra D, Pradhan BK, Mohapatra BP, Swain D. A clinical comparison between 0.5% levobupivacaine and 0.5% levobupivacaine with dexamethasone 8 mg combination in brachial plexus block by the supraclavicular approach. *Indian J Anaesth* 2017;61:302-7. [https://doi.org/10.4103/ija.IJA\\_509\\_16](https://doi.org/10.4103/ija.IJA_509_16)
  28. Park MC, ElAttrache NS, Ahmad CS, Tibone JE. "Transosseous-equivalent" rotator cuff repair technique. *Arthroscopy* 2006;22:1360.e1-e5. <https://doi.org/10.1016/j.arthro.2006.07.017>
  29. Persec Z, Persec Z, Kopljar M, Zupcic M, Sakic L, Zrinjscak IK, et al. Low-dose dexamethasone with levobupivacaine improves analgesia after supraclavicular brachial plexus block. *Int Orthop* 2014;38:101-5. <https://doi.org/10.1007/s00264-013-2094-z>
  30. Rosenfeld D, Ivancic M, Hattrup S, Renfree K, Watkins A, Hentz J, et al. Perineural versus intravenous dexamethasone as adjuncts to local anaesthetic brachial plexus block for shoulder surgery. *Anaesthesia* 2016;71:380-8. <https://doi.org/10.1111/anae.13409>
  31. Sabesan VJ, Shahriar R, Petersen-Fitts GR, Whaley JD, Bou-Akl T, Sweet M, et al. A prospective randomized controlled trial to identify the optimal postoperative pain management in shoulder arthroplasty: liposomal bupivacaine versus continuous interscalene catheter. *J Shoulder Elbow Surg* 2017;26:1810-7. <https://doi.org/10.1016/j.jse.2017.06.044>
  32. Shishido H, Kikuchi S, Heckman H, Myers RR. Dexamethasone decreases blood flow in normal nerves and dorsal root ganglia. *Spine*

- (Phila PA 1976) 2002;27:581-6. <https://doi.org/10.1097/00007632-200203150-00005>
33. Takada M, Fukusaki M, Terao Y, Yamashita K, Takada M, Ando Y. Postoperative analgesic effect of preoperative intravenous flurbiprofen in arthroscopic rotator cuff repair. *J Anesth* 2009;23:500-3. <https://doi.org/10.1007/s00540-009-0799-3>
  34. Taniguchi N, Suenaga N, Oizumi N, Miyoshi N, Araki N, Chosa E. Surface-holding repair: an original arthroscopic rotator cuff repair technique. *J Shoulder Elbow Surg* 2014;23:620-7. <https://doi.org/10.1016/j.jse.2014.01.007>
  35. Uquillas CA, Capogna BM, Rossy WH, Mahure SA, Rokito AS. Postoperative pain control after arthroscopic rotator cuff repair. *J Shoulder Elbow Surg* 2016;25:1204-13. <https://doi.org/10.1016/j.jse.2016.01.026>
  36. White PF. The role of non-opioid analgesic techniques in the management of pain after ambulatory surgery. *Anesth Analg* 2002;94:577-85. <https://doi.org/10.1097/00000539-200203000-00019>
  37. Williams G Jr, Kraeutler MJ, Zmistowski B, Fenlin JM Jr. No difference in postoperative pain after arthroscopic versus open rotator cuff repair. *Clin Orthop Relat Res* 2014;472:2759-65. <https://doi.org/10.1007/s11999-014-3715-6>